

Mastocytosis Society Canada Medical Lecture – June 6, 2011

Contact: [info@mastocytosis.ca](mailto:info@mastocytosis.ca) or [afrin@musc.edu](mailto:afrin@musc.edu)

Systemic Mast Cell Disease: An Update – L. Afrin, M.D., Medical University of South Carolina



2 Glenroy Road, London, Ontario  
Canada N5Z 3K9

ph:- 519.680.3564 | email:- [info@mastocytosis.ca](mailto:info@mastocytosis.ca)  
[www.mastocytosis.ca](http://www.mastocytosis.ca) | [cmsadmin.proboards.com](mailto:cmsadmin.proboards.com)

**Transcript of Mastocytosis & MCAS Medical Lecture held June 6, 2011,  
At Women's College Hospital in Toronto, Ontario, Canada**

Hosted by Dr. Gary Sibbald and Mastocytosis Society Canada (MSC)

Featured Speaker: Lawrence B. Afrin, M.D., Associate Professor of Medicine, Division of Hematology/Oncology, Medical University of South Carolina, Charleston, SC, USA

*Note from Dr. Afrin: The slides included in this document are copied from my original PowerPoint presentation. Some of the slides were "builds," and thus if the image on a slide copy included in this document doesn't make sense, it's because you're seeing the final image resulting from a series of images that made a lot more sense as they were incrementally revealed during the slide presentation.*

**Please note this presentation is copyright © 2011 by Lawrence B. Afrin, M.D. and the Medical University of South Carolina. You are welcome to use any or all parts of this presentation for educational purposes, but please contact me ([afrin@musc.edu](mailto:afrin@musc.edu)) before using any part for commercial or other purposes.**

**Dr. Sibbald:** Welcome, everybody. My name, and I think I know most of you, is Dr. Gary Sibbald, and I'm a dermatologist and an internist. It's interesting: 30 years ago I did a whole year of study on mast cell disease at St. John's Hospital for Diseases of the Skin, a University in London (UK) with Dr. Malcolm Greaves who is one of the world's experts on the mast cell. I've had a smoldering interest since that time. We'll introduce Dr. Lawrence Afrin as an Associate Professor of Medicine at the University of South Carolina in Charleston (South Carolina, USA).

Dr. Afrin has had an interest in mast cell disease and a perspective on a component called mast cell activation disease. But I think for everybody's sake and for Dr. Afrin, I'm going to ask everyone to introduce themselves and say what your relationship or interest is in mast cell disease. Shelley, you're behind the camera, so why don't you start?

**Shelley Darcy:** I'm Shelley Darcy (Director of MSC). I live in North Bay (Ontario, Canada). I was diagnosed by Dr. Afrin through a business dinner that he had with my husband just from explaining the symptoms that I had. I had thyroid cancer, positive in lymph nodes, in 2004, and then I had roughly 27 syncopal episodes between January and June of 2005. I was hospitalized 6 times, I think, for periods of times. I was always released from the hospital with an undetermined diagnosis. During the dinner (with my husband Marc and Dr. Afrin), Marc got me on the phone with Dr. Afrin. We spoke briefly about my symptoms. He sent an eight page e-mail which I then forwarded to my endocrinologist, and subsequently it was just basically, luckily for me, a tryptase test that

was elevated. And with the elevation of the tryptase, Dr. Afrin then provided guidance to answer, “where is this coming from?” So I was then introduced to Dr. Gill, a hematologist at the cancer centre in Sudbury (Ontario, Canada). I was also a patient of his for the thyroid cancer. Subsequently I had the bone marrow test which also proved the diagnosis of mastocytosis. That was in 2009. I’ve been on a host of medications and am still trying to find the best personal cocktail for me because what I’m learning is that it’s very unique to each of us in terms of the types of medications that work for each of us. Dr. Afrin has been instrumental in my initial diagnosis. Carrie D’Arville from MSC, who I quickly learned about after my diagnosis, introduced me to Dr. Sibbald. As I’ve learned, in the medical profession mast cell disease is a very difficult area, and the expertise of the doctor is less important than the passion he exhibits in terms of the care that we receive. And so I believe the two of these gentlemen as physicians from a mastocytosis perspective are paramount in terms of the passion that they demonstrate. And the opportunities that they give all of us to have a better quality of life by working with us on an individual basis. I’m grateful to be here, and I’m grateful to Carrie because I wouldn’t be here if it wasn’t for her and these two great physicians, so that’s my story.

**Joan Parkes:** I’m a patient of Dr. Sibbald, and I have mastocytosis. Recently I had been having trouble finding out my diagnosis. It took very little time for Dr. Sibbald to make a diagnosis after two years of being passed from person to person without understanding what my problem was, so I’m very grateful to him.

**Joel Parkes:** I’m Joel Parkes and I’m a retired chemist. I’m here just as Joan’s husband and an interpreter.

**Dr. Sibbald:** Dr. Parkes was a Professor at University of Toronto for many years.

**Joel Parkes:** I wasn’t a Professor. I was a Research Associate at the University of Toronto for many years. I’ve been retired since 2002 and luckily was seeing Dr. Sibbald for another condition and was curious about Joan’s dermatographia – that was her initial finding – and Dr. Sibbald put her on doxepin and cetirizine for managing the histamine levels in response to the receptors, so I was somewhat involved in that case, but totally by accident.

**Mark Irish:** I’m Mark Irish. I’m a patient of Dr. Sibbald and a volunteer for MSC. I have mastocytosis, obviously. I also have Charcot-Marie Tooth Type 5, so I have a neurological condition as well, and I’m just here to learn.

**Carrie D’Arville:** I’m Carrie D’Arville. I’m the President of MSC and one of several co-founders. MSC is very much a group effort by patients, and Dr. Sibbald, as our main doctor and our main advisor, has helped us a lot. I have TMEP mastocytosis as well as a systemic diagnosis by my hematologist in London, Ontario, despite not meeting the WHO (World Health Organization) criteria for the systemic form of mastocytosis. I have also, based on my presentation to my hematologist, been told, “You are definitely

systemic,” so I’ve just gone with that and treated it as such. Dr. Sibbald is my primary mastocytosis physician for all of it.

**Dr. Johnston:** My name is Dr. Johnston. I’m a community psychiatrist. Just retired actually but introduced to this whole topic by Sarah Leach and just fascinated with the widespread subject matter of this and how many fingers go out from it to other illnesses and just find it very interesting.

**Dr. Sibbald:** It is very interesting. We did a paper with a professor at the University of Toronto on the many faces of mastocytosis. Often people are told they’re crazy and went, on average, up to 10 years without a diagnosis.

**S. J. Milne:** I’m Dr. Milne. I’m the mother of Sarah Leach. I’m a physician in Sudbury (Ontario, Canada). I have a practice focused on child mental health, and I’m here primarily because of my daughter.

**Sarah Leach:** I’m Sarah Leach, and I’m a patient of Dr. Sibbald as well. I had been getting sick for many, many years and have been diagnosed with different things. By last year I was bedridden and completely non-functional. After learning about mast cell disease and starting on antihistamines and mast cell stabilizers, I’ve gotten a little bit better. I’m here as a patient as well. Dr. Afrin has been incredibly kind to me, sending me information by e-mail.

**Cathryn Sibbald:** My name is Cathryn Sibbald. I’m a second year medical student and Dr. Sibbald’s daughter.

**David Girvin:** My name is David Girvin, and Dr. Sibbald is my dermatologist. I’ve had a fairly unusual experience in that Dr. Sibbald, every 6 months, will take off a couple of basal cell carcinomas, but almost by coincidence, I guess, we also made a diagnosis of idiopathic cutaneous mastocytosis. It’s nice to have control with a good doctor.

**Dr. Werb:** I’m Dr. Marsha Werb. I’m an endocrinologist. It’s interesting how you get this kind of patient in your practice. I remember going to a Mayo Clinic conference on endocrinology on something called “Spells,” and the thing about spells is that they can be mastocytosis or of other endocrinologic origin. Often these are patients with POTS or whatever, and you just don’t know what you’re getting into your hands. It sounds nice to hear other specialists dealing with spells.

**Marc Rancourt:** I’m Marc Rancourt. I’m Shelley’s husband, and I’m just here to listen and help.

**Dr. Monthrope:** I’m Yvette Monthrope. I’m a dermatologist here at Women’s College Hospital (Toronto, Ontario). I actually didn’t know about this and then I saw Tina (Dr. Trinkaus), who I went to medical school with, on the 8th floor. And I had just finished

Mastocytosis Society Canada Medical Lecture – June 6, 2011

Contact: [info@mastocytosis.ca](mailto:info@mastocytosis.ca) or [afrinl@musc.edu](mailto:afrinl@musc.edu)

Systemic Mast Cell Disease: An Update – L. Afrin, M.D., Medical University of South Carolina

with my last patient upstairs who I just biopsied because of suspected cutaneous mastocytosis. It's my first one, actually, since I graduated last year, and so then I said, "it must be a sign" because Tina's coming to this conference, so I came with her.

**Dr. Trinkaus:** I'm Tina Trinkaus. I'm a hematologist at St. Michael's Hospital (Toronto, Ontario). We see a handful of patients every month or so who have mast cell disease in our allergy practice, and so I'm here for the education.

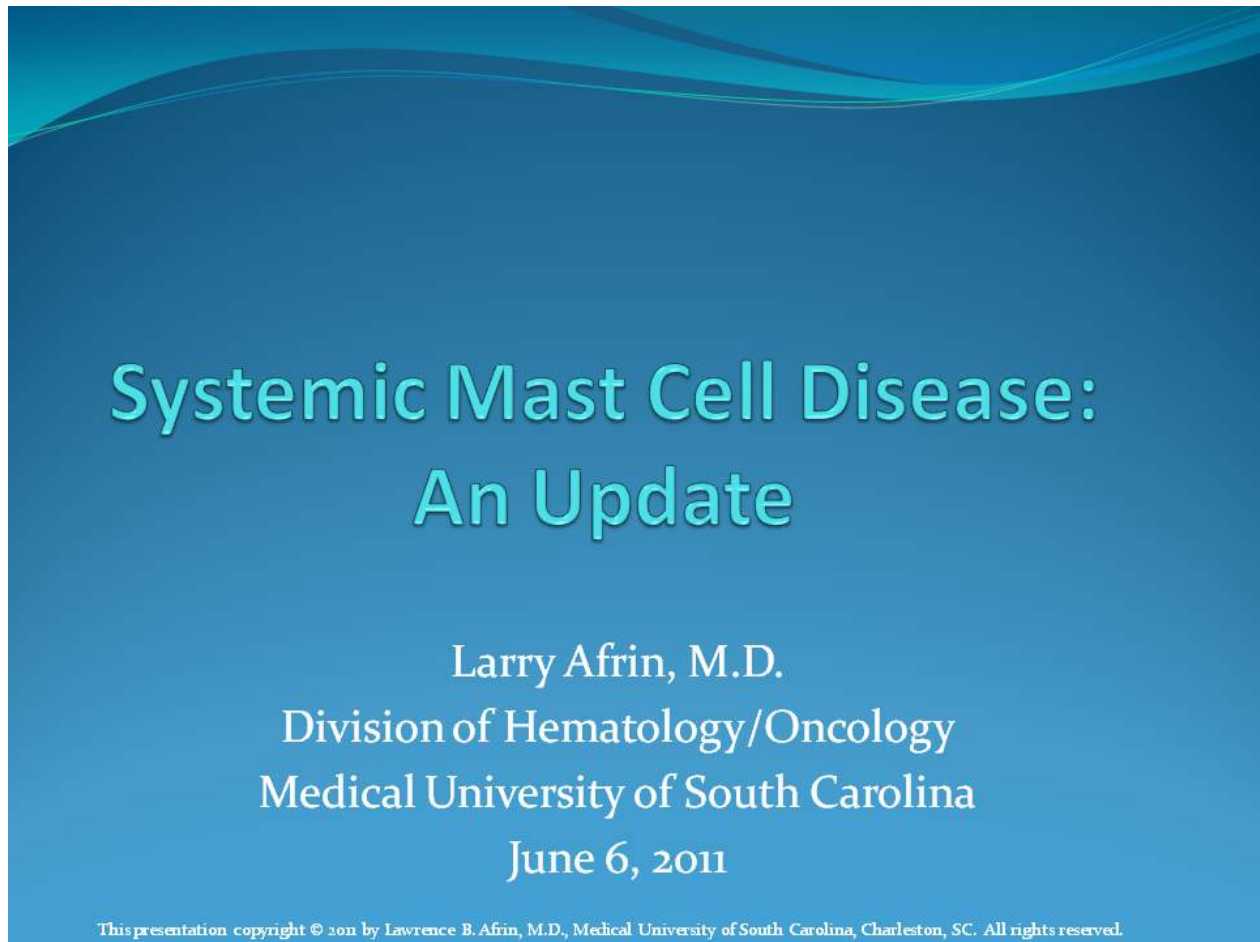


Mastocytosis Society Canada Medical Lecture – June 6, 2011

Contact: [info@mastocytosis.ca](mailto:info@mastocytosis.ca) or [afri@muscd.edu](mailto:afri@muscd.edu)

Systemic Mast Cell Disease: An Update – L. Afrin, M.D., Medical University of South Carolina

[Slide 1: Title Slide: Systemic Mast Cell Disease: An Update]



The slide features a blue background with a wavy pattern at the top. The title 'Systemic Mast Cell Disease: An Update' is centered in a large, light blue, sans-serif font. Below the title, the presenter's name 'Larry Afrin, M.D.' and affiliation 'Division of Hematology/Oncology, Medical University of South Carolina' are listed in a smaller, white, serif font. The date 'June 6, 2011' is centered below the affiliation. At the bottom, a small white font contains the copyright notice: 'This presentation copyright © 2011 by Lawrence B. Afrin, M.D., Medical University of South Carolina, Charleston, SC. All rights reserved.'

**Dr. Afrin:** I'm Larry Afrin, from the Medical University of South Carolina in Charleston. First I'd like to clarify I did not diagnose Shelley over a dinner table. That's not the way to make a diagnosis. Rather, I *suspected* she had mast cell disease based on what Marc was telling me. She then underwent appropriate testing, and her tests were what confirmed the diagnosis.

[Slide 2: Learning Objectives & Disclaimers]

## Learning Objectives & Disclaimers

- Learning Objectives
  - Understand the heterogeneous presentation of systemic mast cell disease
  - Understand the current approach to diagnosing and treating systemic mast cell disease
  - Describe the principal differences between mastocytosis and mast cell activation syndrome
- Disclaimers/Conflicts of Interest
  - None

These are the objectives of my talk. When Shelley told me that this was going to run from 4:30 to 6:30, I came up with a presentation that's a little bit longer than the standard one hour. I've worked in quite a number of case presentations sprinkled throughout so that I can better address point one here, the extreme clinical heterogeneity of mast cell disease which I think is a major barrier to diagnosis, and I wanted to give as much of a flavour of that heterogeneity as I could. So I've worked in a number of case presentations that's going to make this overall presentation run a little bit longer than an hour, but for those of you who can stay that long, I promise you that if you stick around to the last case presentation, you will find it worthwhile for as thought-provoking a case as it's going to be.

[Slide 3: Overview]

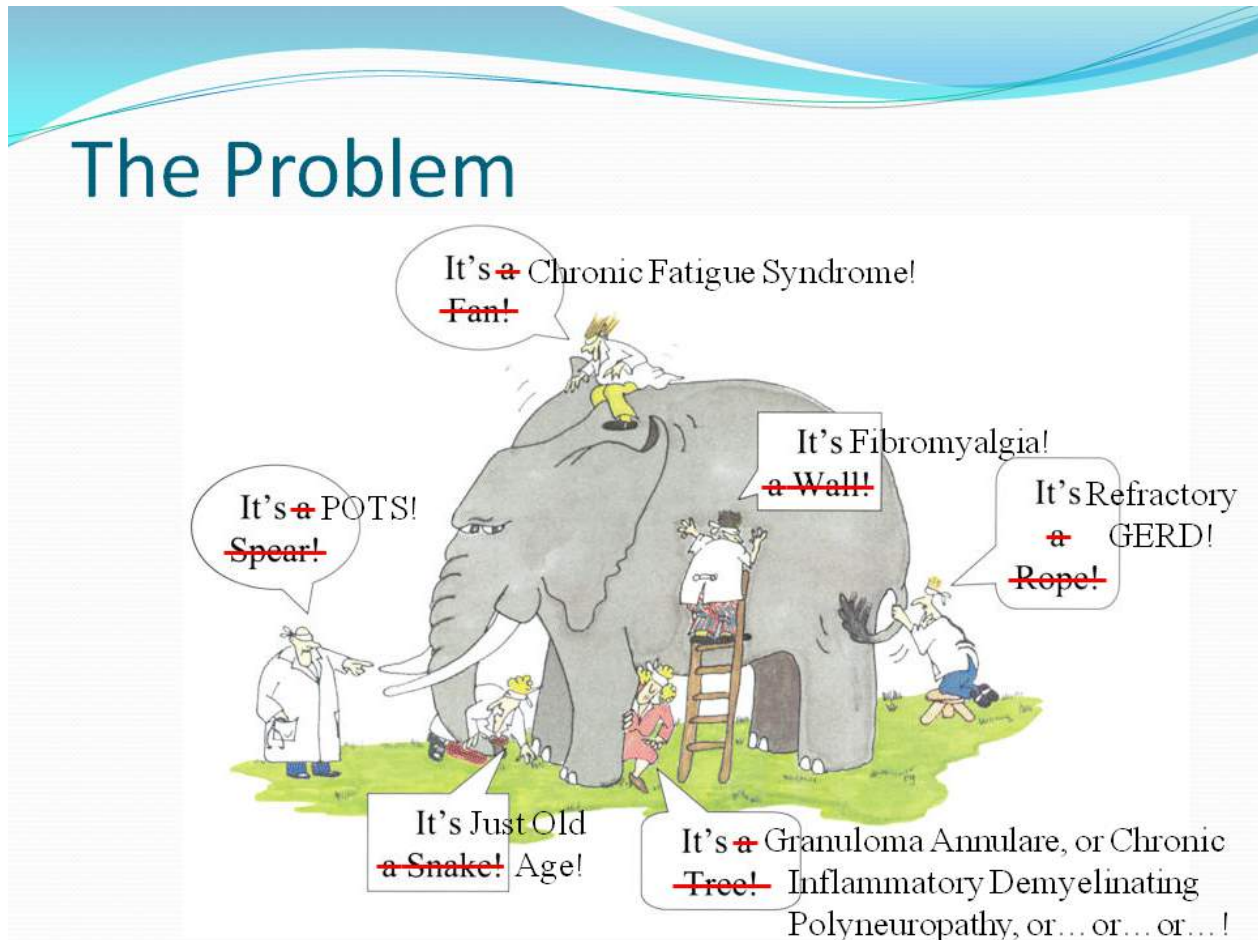
## Overview

- Systemic Mastocytosis
  - History
  - Biology
  - Diagnosis
- Mast Cell Activation Syndrome
  - Biology
  - Presentation
  - Diagnosis
  - Treatment
  - Prognosis
- What's next?

We'll go over the current approach to diagnosing and treating systemic mast cell disease and the principal differences between mastocytosis and mast cell activation syndrome (MCAS). I don't have any financial disclaimers or conflicts of interest.

This is a small group, so let's keep it informal. I do tend to speak rapidly, I do have a lot of slides, and I don't expect you to read everything that's on every slide. I'm going to just try to highlight the most important points on each slide, so feel free to interrupt me at any point; I'm perfectly OK with that.

[Slide 4: The Problem]



You will not find another disease besides systemic mast cell disease that better illustrates the old “four blind men and an elephant” problem. There are lots of factors that go into every specialist looking at a patient with mast cell disease from a different perspective, seeing only the problems that they’ve been taught to see in their own domain. And in the first 13 years of my career post-fellowship, I practiced that way, too. As just one example, I can’t begin to count the numbers of patients I’ve seen in that time who’ve had “anemia of chronic inflammation.” Mysterious anemia, nobody knows why, no clear source of the chronic inflammation, and we just leave it at that. And it’s acceptable in the medical community to just leave it at that. For lots of reason (many relating to our healthcare financing systems), the physician can’t spend nearly as much time with each patient as would be needed or desirable to get to the root of every mystery. So the hematologist sees the anemia, the gastroenterologist sees the irritable bowel syndrome, the rheumatologist sees the fibromyalgia, the cardiologist sees the palpitations, the neurologist sees the migraine headaches and neuropathy, and so on and so forth. We all just constantly miss the elephant.

[Slide 5: Two illustrative, polar opposite cases.]

Two illustrative, polar opposite cases...

Polycythemia



Pure red cell aplasia

So I'm going to start this presentation by illustrating the heterogeneity of systemic mast cell disease with a couple of polar opposite cases.



[Slide 6: Polycythemia.]

## Polycythemia

- In the 1980s an athletic 30ish businesswoman, long a coastal resident, began noticing intermittent migratory erythematous rash on brief sun exposure.
- Over time chronic waxing/waning fatigue set in, mild at first, worsening over time.
- 1992: Idiopathic bradycardia, spontaneously resolving after a few months.
- 1998: Onset of episodic vertigo and episodic pruritus, both slowly but steadily worsening in severity and frequency.

Afrin LB. Polycythemia from Mast Cell Activation Syndrome: Lessons Learned. *Am J Med Sci* 2011 July, in press.

This is the first person in whom I diagnosed MCAS, a term which, at the time this patient presented to me in 2008, was just coming into existence. She was a lady who back in the 1980's was an athletic 30ish businesswoman, long a coastal resident, so her primary presenting issue of polycythemia – too many red blood cells – was not an issue of her living at high altitudes and having low oxygen in her blood. She began noticing intermittent migratory red rash on brief sun exposure. This was not sunburn. Over the years chronic waxing and waning fatigue set in, worsening over time. In retrospect we eventually learned that she had had a number of other problems, too, which developed over time including some heart rhythm issues, vertigo, and itching, all of it following a waxing and waning course that over time gradually worsened in severity and frequency.

[Slide 7: Polycythemia.]

## Polycythemia

- 2003: Began falling during daily jogs.
- She presented for evaluation in 2005. Physical examination was unremarkable. Routine blood counts and chemistries were notable only for H/H 15.9/50 (normocytic). She was referred to a hematologist.
- No other complaints were elicited. Exam was again normal. Red cell mass and plasma volume were both ~10% above normal. No other tests were performed.
- P. vera (PV) was diagnosed. Phlebotomy was begun. She became anemic and iron-deficient. She felt steadily worse.

Afrin LB. Polycythemia from Mast Cell Activation Syndrome: Lessons Learned. *Am J Med Sci* 2011 July, in press.

She began falling during her daily jogs. She was an independent businesswoman, a real go-getter, but she finally became sufficiently fatigued that she presented to her primary internist in 2005 and he did the appropriate thing for somebody complaining of fatigue. He checked her blood counts. To his surprise, she was not anemic. Rather, she was polycythemic, but she had just a mild degree of polycythemia. She was referred to a local hematologist, who didn't elicit her other complaints that had been accruing over the prior 20 years. The exam was normal. He ran a single test looking for a chronic hematologic malignancy called polycythemia vera. The nuclear red cell mass study came back minimally abnormal. And despite the fact that at the time you needed a lot more than just that one test to diagnose polycythemia vera, he stopped at that point based on that abnormality. He made a diagnosis of polycythemia vera, and he started giving the appropriate treatment for that diagnosis, namely, phlebotomy, literally draining blood out of her periodically so that he could make her iron-deficient and thereby prevent the bone marrow from continuing to make this excess quantity of red blood cells.



[Slide 8: Polycythemia.]

## Polycythemia

- Vague chronic waxing/waning gastrointestinal discomforts emerged. She began noticing lability in pulse, blood pressure, subjective temperature.
- 2006: Slow to heal from a knee replacement.
- 2007: Ceased exercising due to worsening fatigue and unprovoked episodes of dyspnea, tachypnea, and labile BP; cardiology consultation attributed symptoms to PV.
- 2007: Episodic insomnia

Afrin LB. Polycythemia from Mast Cell Activation Syndrome: Lessons Learned. *Am J Med Sci* 2011 July, in press.

It's a general principle of medicine that if you have the right diagnosis and you get the right treatment, you usually get better. But she just kept getting worse. She began developing a variety of gastrointestinal discomforts and then started developing marked lability in her vital signs. She would have her temperature shoot up, her temperature shoot down, her blood pressure shoot up, her blood pressure shoot down, and so on and so forth. She also began developing problems with healing from minor wounds.

By 2007, the year before she saw me, she ceased exercising due to worsening fatigue and unprovoked episodes of shortness of breath, then spells of breathing too fast, and labile blood pressure as well. She saw a cardiologist who attributed all of this to polycythemia vera despite that disease not being able to cause most of these symptoms, but the patient, of course, didn't know any better. She also developed sleeping problems. And then things started getting a lot worse.

[Slide 9: Polycythemia.]

## Polycythemia

- 2008: Multiple unprovoked episodes of severe nausea, anorexia, pallor, mild hypotension, and chills (without fever), attributed to URIs though no infectant could be found and antibiotics all caused rashes. Ceased working. Her requests for referral for a 2<sup>nd</sup> opinion were declined. She referred herself for a 2<sup>nd</sup> opinion.
- No snoring or apnea. No relevant family, social history.
- Meds: metoprolol, HCTZ, fish oil, estrogen, esomeprazole, aspirin. No epo use. No allergies.
- Exam unremarkable, O<sub>2</sub> saturation 100%

Afrin LB. Polycythemia from Mast Cell Activation Syndrome: Lessons Learned. *Am J Med Sci* 2011 July, in press.

In early 2008, multiple, much more severe spells developed. We don't need to go through all the details here, but her requests for a second opinion were repeatedly refused based on her hematologist's confidence in the diagnosis of polycythemia vera based on that minimally abnormal red cell mass study. Since she was not responding to treatment, her hematologist chose to increase the intensity of the treatment. So she did something that relatively few patients do: she referred herself for a second opinion. On history, she did not have any other issues that could cause a low oxygen level, and in fact, when tested, she did not have a low oxygen level. Her oxygen saturation was fine, her examination was fine (other than her obvious fatigue), and she was taking only a few medications prescribed by her other doctors for some of the symptoms she was having. With regard to allergies, she claimed not to have any allergies, but a careful history revealed in just the prior few months she had begun having reactions to many antibiotics that were being tried for her alleged upper respiratory infections which really looked and behaved like infections except no infectant could ever be found.

[Slide 10: Polycythemia.]

## Polycythemia

- Mild anemia and thrombocytosis, iron deficiency, WBC/diff nl. except 3% basophils
- Minimally elevated: ESR and epo
- Moderately elevated: LDL, triglycerides, plasma free norepinephrine and dopamine
- Normal: ESR, CRP, SPEP, quant. Igs, LDH, B<sub>12</sub>, AFP, U/A, 24-hour urinary catechols/metanephrines/VMA/HVA/5-HIAA/N-methylhistamine, clonidine suppression test, serum and urine porphyrins, tryptase, serotonin, CEA, calcitonin, chromogranin A
- Absent: JAK<sub>2</sub>, MPL mutations.

Afrin LB. Polycythemia from Mast Cell Activation Syndrome: Lessons Learned. *Am J Med Sci* 2011 July, in press.

So when I evaluated her, I found mild anemia from her being phlebotomized by her hematologist, a corresponding iron deficiency which can also cause an elevation in the platelet count (i.e., a thrombocytosis), a normal white blood cell count, and a normal white blood cell differential (the breakdown of different types of white blood cells) except she had a very modest increase in a type of white blood cell called a basophil. There were a number of other abnormalities, too. I'll summarize and tell you that it was immediately obvious from her history that she couldn't possibly have polycythemia vera because p. vera doesn't behave the way she was behaving. So then it became a question of what can a person have that causes not only modest polycythemia but also all of these other problems she's had? It quickly boiled down to possibly a very weird form of a rare adrenal tumour called pheochromocytoma (which wasn't a good fit because that should make you episodically have increased blood pressure and pulse, not low blood pressure and pulse) or mast cell disease. I ran a number of tests looking for evidence of mast cell disease including serum tryptase and serum and urine histamine assessments and other assays, but they were all negative. The testing was extensive, but I felt compelled to identify what had ruined a previously highly productive

Mastocytosis Society Canada Medical Lecture – June 6, 2011

Contact: [info@mastocytosis.ca](mailto:info@mastocytosis.ca) or [afrinl@muscc.edu](mailto:afrinl@muscc.edu)

Systemic Mast Cell Disease: An Update – L. Afrin, M.D., Medical University of South Carolina

woman's life. I refused to believe that she had a new disease. I believe that, except in rare cases of new infections emerging by mutation from existing infectants or by transmission of infection to humans from non-human sources, there are no new diseases under the sun. So we just had to keep at it until we figured out what she had. Perhaps I would not have been able to treat it, but if we could at least make a diagnosis, then we could establish a prognosis, and that helps ease patients' minds at least a little bit, to at least have a diagnosis and prognosis.



[Slide 11: Polycythemia.]

## Polycythemia

- Normal: Abd/pelv MRI, MIBG, PET
- Rash biopsy: “dense infiltrate urticaria,” no mast cells
- Marrow aspiration/biopsy: mild trilineage dysplasia, megaloblastic changes, absent iron, otherwise nl. (histology, flow, cytogenetics, TCRGR, KIT-D816V).
- Repeat of all labs (including 24-hour urine collected during an “episode”) were again all normal
- 24-hour urinary prostaglandin D<sub>2</sub> was mildly elevated

Afrin LB. Polycythemia from Mast Cell Activation Syndrome: Lessons Learned. *Am J Med Sci* 2011 July, in press.

Extensive testing continued including abdominal MRI's and a PET scan (looking for other types of tumors which rarely produce a hormone which can cause excessive red blood cell production), a biopsy of her skin rash (which showed no mast cells, just urticaria), and a bone marrow biopsy on which extensive testing for mast cell disease was all negative. I then repeated all of the labs because by this point I was beginning to learn (by reading about mast cell disease in the medical literature) that the disease can go through waxings and wanings in various symptoms and mediators. Everything was again normal except, finally, a 24-hour urinary prostaglandin D<sub>2</sub> (PGD<sub>2</sub>) was mildly elevated. So I told the patient that, from a clinical perspective, I thought she had mastocytosis. I had one marker (PGD<sub>2</sub>) that was positive, and PGD<sub>2</sub> is highly sensitive and specific for mast cell activation.

There are very few types of cells in the human body that are capable of making PGD<sub>2</sub>, and the other cells (besides the mast cells) that are capable of making it can't make it in anywhere near the quantities that the mast cell can make it. So we had marker evidence and symptomatic evidence of abnormal mast cell activation. The next question became,

where is the disease (i.e., the abnormally functioning mast cells) hiding? If it's not in the bone marrow and it's not in the skin, where is it? In my readings, I had learned that these cells, in order to fulfill their primary biologic function, tend to hang out at the environmental interfaces. So if it's not in the skin and not in the marrow, that pretty much leaves the respiratory tract and GI tract for the most part, perhaps even the GU tract. Safety considerations led to my disfavoring a lung biopsy, so I sent her to the GI endoscopist, and I told him what I was pretty sure he was going to see: "You are going to see a completely normal exam upper and lower endoscopy, but you have to take biopsies because it almost certainly has to be there."

[Slide 12: Polycythemia.]

## Polycythemia

- EGD and colonoscopy were performed.
- All segments appeared normal. The gastroenterologist was persuaded to obtain multiple random mucosal biopsies throughout the upper and lower tracts.
- The pathologist reported all as normal on H&E and initially declined the request for immunohistochemistry and flow cytometry.
- The pathologist was persuaded to pursue immunohistochemistry.

Afrin LB. Polycythemia from Mast Cell Activation Syndrome: Lessons Learned. *Am J Med Sci* 2011 July, in press.

The endoscopist called me during the procedure to report he had examined her entire upper and lower GI tract and it was all normal. He asked whether I was sure I wanted biopsies. I affirmed, and he took the biopsies. They were sent off to the pathologist with instructions to do not only the normal evaluation we call H&E staining but also special immunohistochemistry to identify mast cells. The pathologist called me a week later and told me I was wrong, this was not mast cell disease. I asked, “What is it?” He said, “These are the most normal GI mucosal biopsies I’ve ever seen. This is ‘textbook normal.’ I’ve been doing GI pathology for 30 years, and it doesn’t get more normal than this.” And then I asked him a question that I already knew the answer to. I asked, “Did you do the special immunohistochemistry?” I knew he hadn’t because at that time at my institution, it took 3 weeks to do that immunohistochemistry, yet he had called me after 1 week. He admitted he had not run the special testing and explained by again saying, “It’s the most normal sample I’ve ever seen”. I again explained my strong suspicions, again explained how the patient’s life had been ruined by her disease, and argued for running the special testing. He countered with an argument about the expense of the special testing, and I countered that the financial and, more important, human costs of



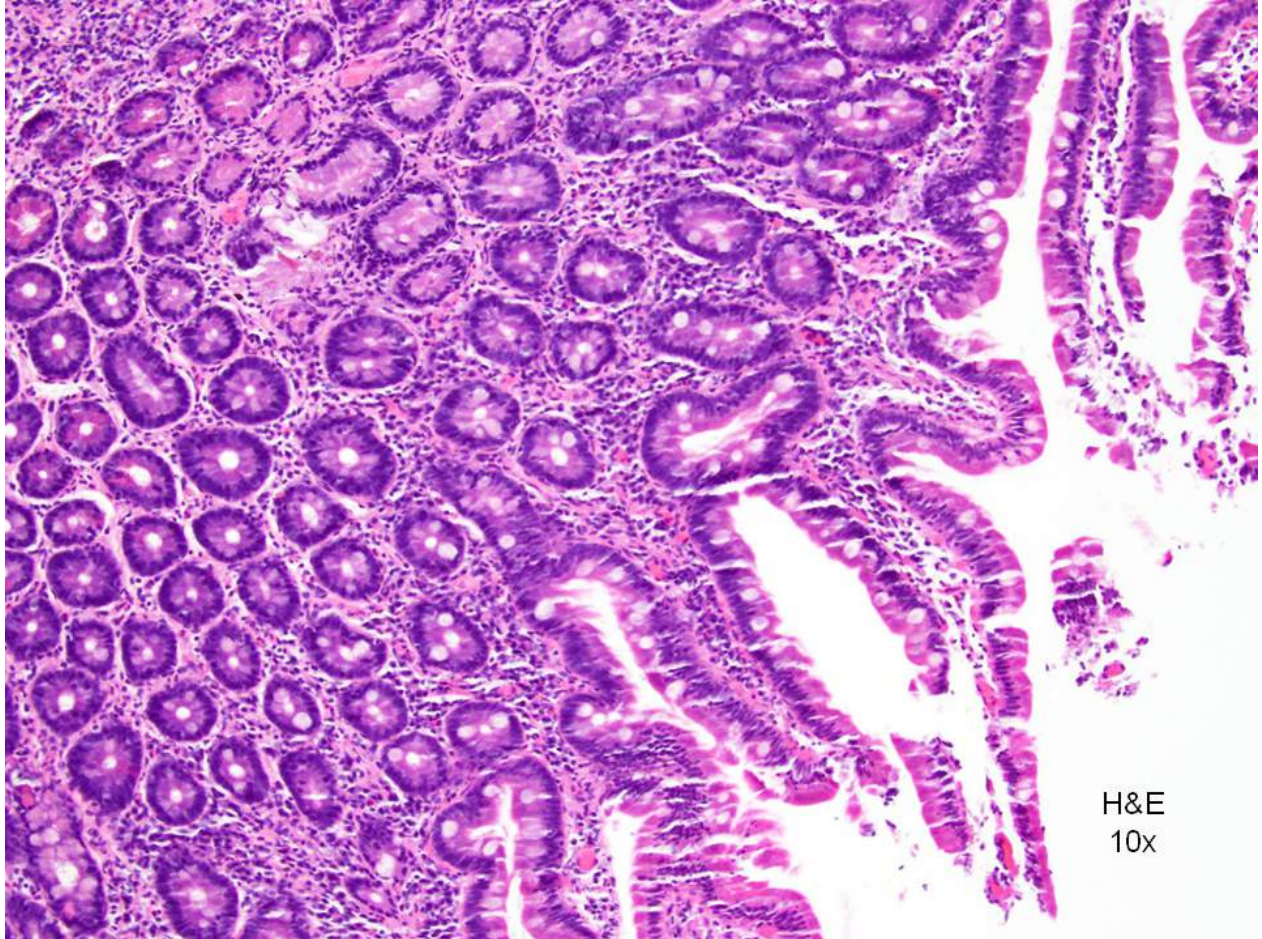
Mastocytosis Society Canada Medical Lecture – June 6, 2011

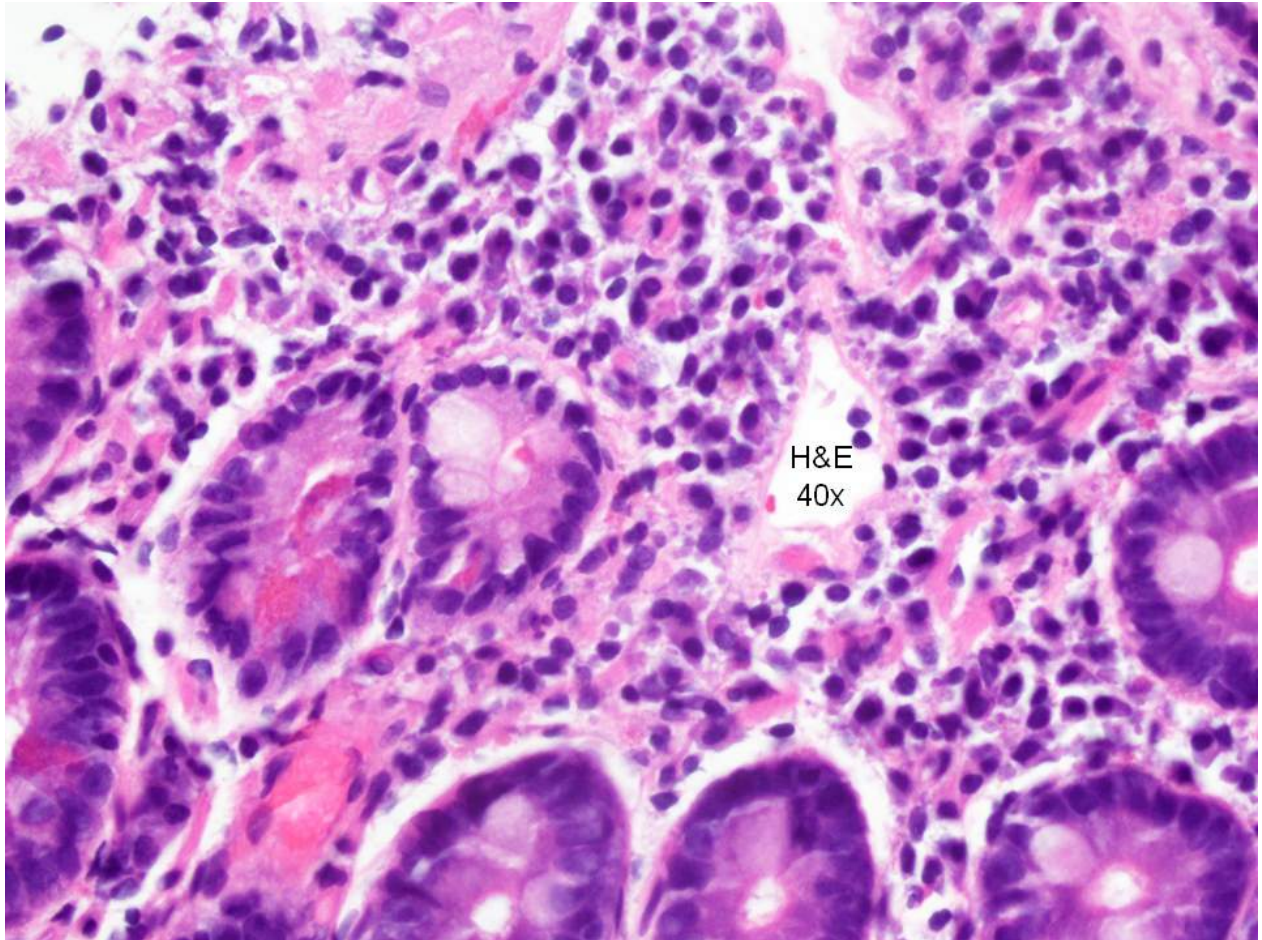
Contact: [info@mastocytosis.ca](mailto:info@mastocytosis.ca) or [afrinl@musc.edu](mailto:afrinl@musc.edu)

Systemic Mast Cell Disease: An Update – L. Afrin, M.D., Medical University of South Carolina

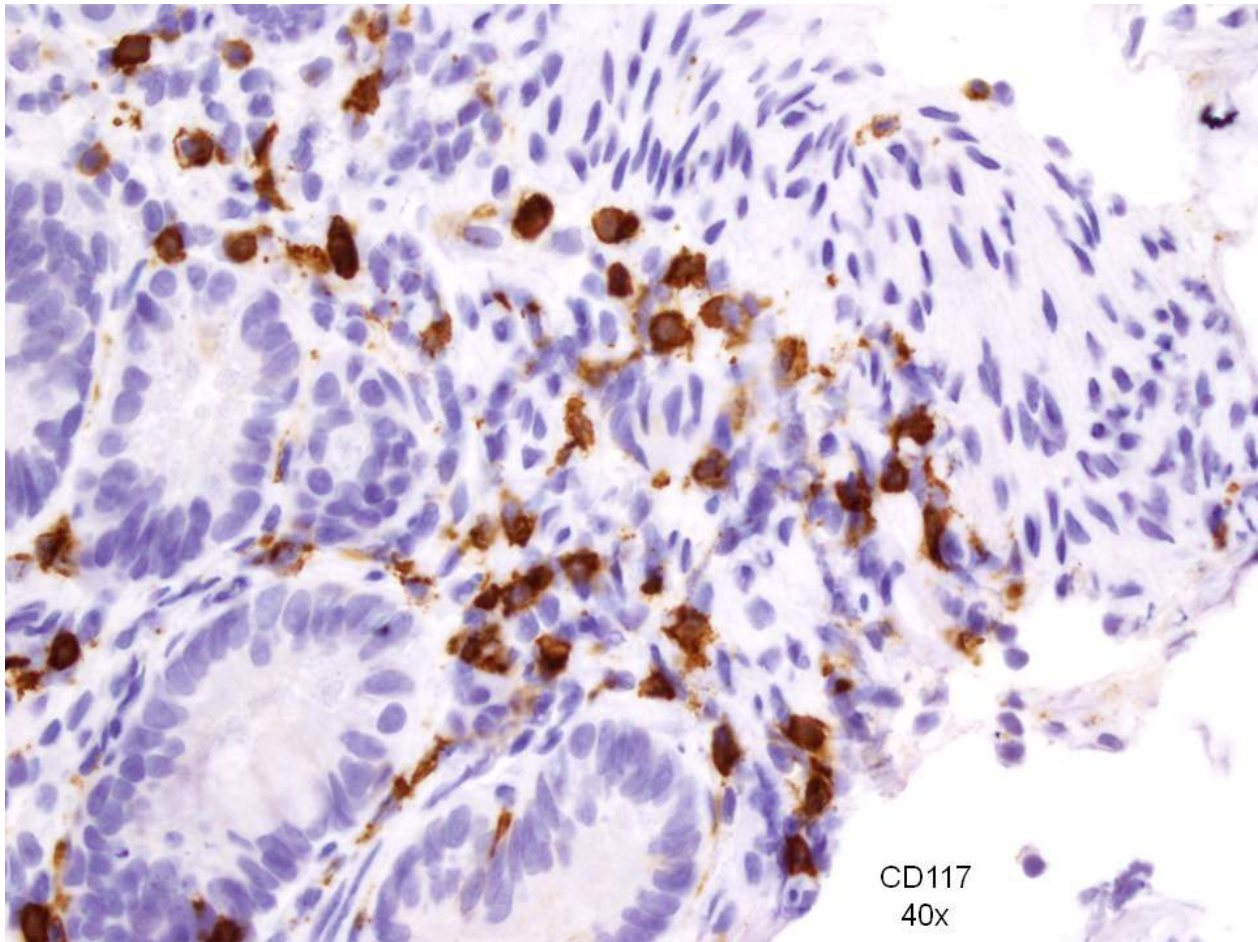
not finding an answer would be far greater. He ultimately agreed to do the special testing.

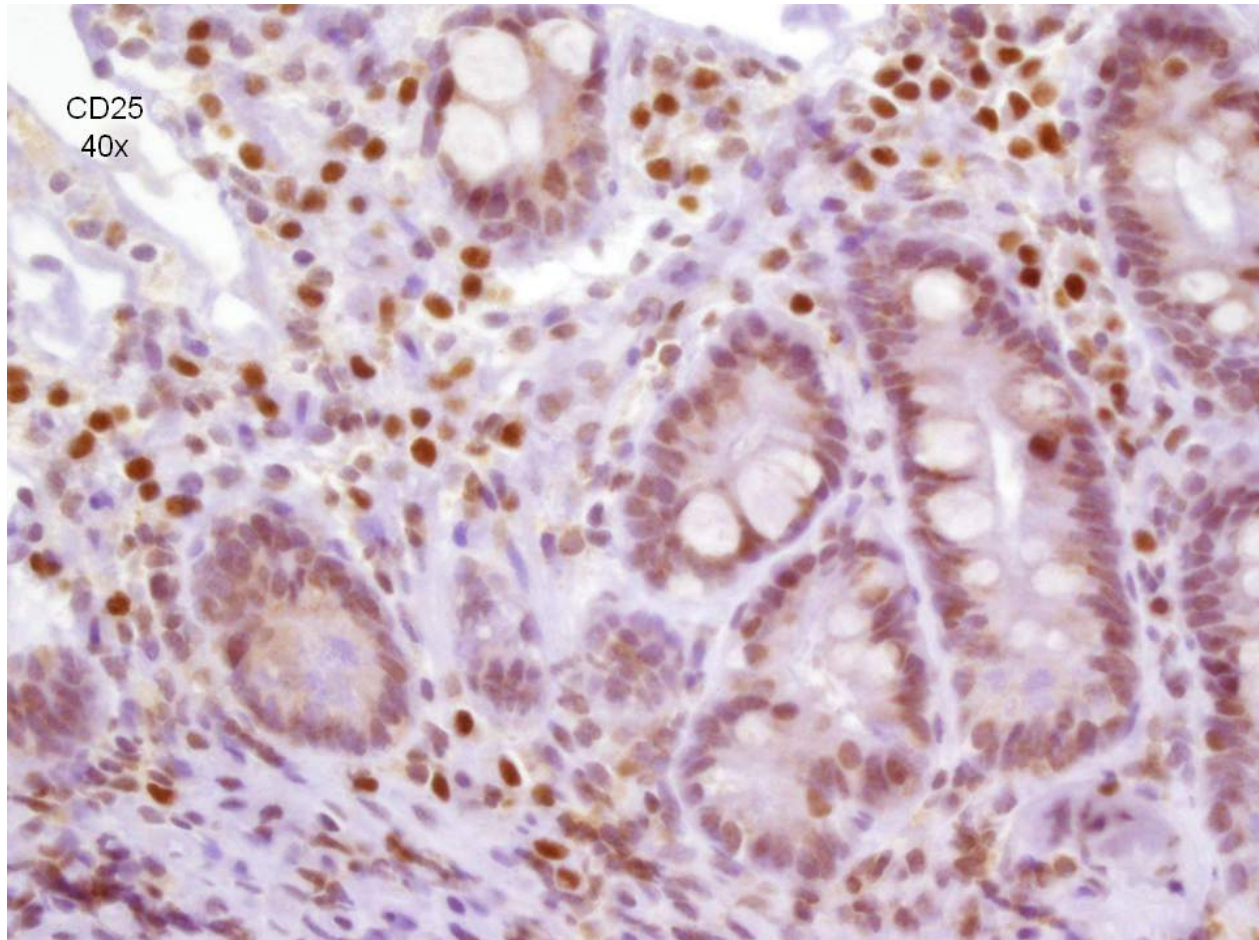
[Slides 13-16: Photomicrographs of duodenal mucosa stained with H&E and with CD117.]











The pathologist called me 3 weeks later and was at a loss for words. “I’ve never seen anything like this before. The H&E stain was completely textbook normal, but the immunohistochemistry stain was completely abnormal.”

These were the biopsies. [Slides 13 and 14] This was the routine staining with H&E, and these results are normal. This is what normal duodenal mucosa is supposed to look like on H&E staining. [Slide 15]. And this was the abnormal staining. Many of the cells that had been thought by the pathologist to be lymphocytes actually were mast cells instead. This is the CD117 stain. [Slide 16] And this is the CD25 stain.

**Dr. Trinkaus:** Sorry, a very quick question. The H&E stain, if he’d done Giemsa or other mast cell stains, would that have been positive?

**Dr. Afrin:** Possibly.

**Dr. Trinkaus:** Possibly?

Mastocytosis Society Canada Medical Lecture – June 6, 2011

Contact: [info@mastocytosis.ca](mailto:info@mastocytosis.ca) or [afrinl@musc.edu](mailto:afrinl@musc.edu)

Systemic Mast Cell Disease: An Update – L. Afrin, M.D., Medical University of South Carolina

**Dr. Afrin:** What I have found in my experience in the last 3 years is that if you've got to pick one stain, the CD117 is the probably the best stain to go with. I prefer to do a battery of stains if possible, but it's not always possible.

[Slide 17: Polycythemia.]

## Polycythemia

- MCAS was diagnosed.
- Imatinib was begun
  - 100 mg/d x 1 week, then
  - 200 mg/d
- The first week: tolerated fine, but no response
- And then, on waking the morning after the fourth dose of 200 mg.....

Afrin LB. Polycythemia from Mast Cell Activation Syndrome: Lessons Learned. *Am J Med Sci* 2011 July, in press.

I called the patient back into the office and told her, “I think we have identified the root of your problem as mast cell disease, but the form of mast cell disease that appears to be in you doesn’t match any diagnostic criteria we’ve got. I don’t know what to call this diagnostically, and from a treatment perspective, there are no guidelines available, either.” We talked about a lot of options, and in my naïveté at the time I decided to recommend a trial of Gleevec (imatinib) as her first-line therapy.

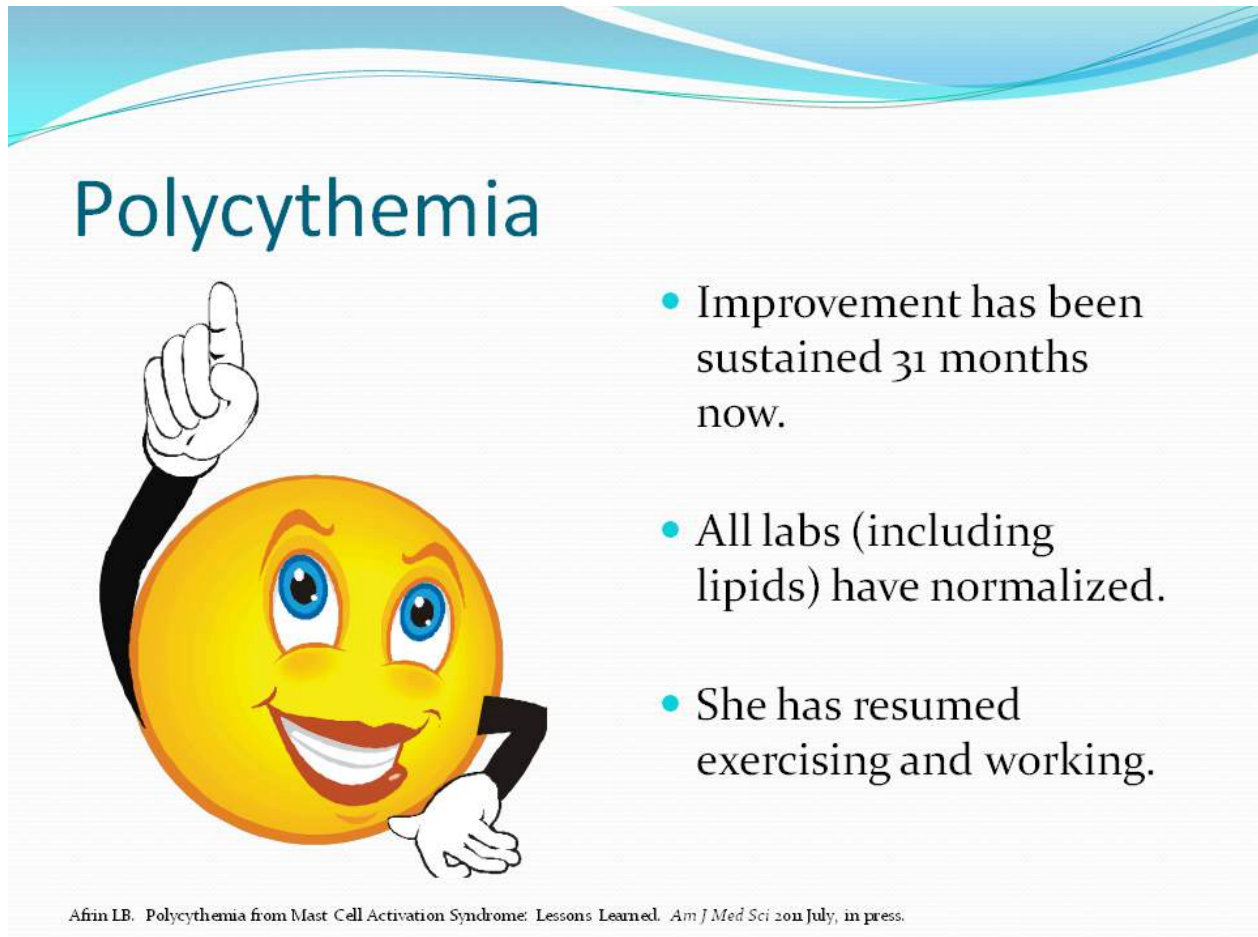
**Dr. Sibbald:** I want you to tell them what Gleevec is.

**Dr. Afrin:** Gleevec is a tyrosine kinase inhibitor, but we’re going to get into these biologic details shortly, so I’d like to defer that for now.

So I started her at the lowest available dose and instructed her to double it after a week if she were tolerating it OK but hadn’t noticed any improvement.



[Slide 18: Polycythemia.]



## Polycythemia

- Improvement has been sustained 31 months now.
- All labs (including lipids) have normalized.
- She has resumed exercising and working.

Afrin LB. Polycythemia from Mast Cell Activation Syndrome: Lessons Learned. *Am J Med Sci* 2011 July, in press.

She returned a month later. When I walked in the exam room, the difference was stark. She was beaming, a big smile on her face; she was radiating energy. I asked, “What happened?” She said, “The first week, nothing happened. So then I doubled the dose, as you said.” She woke on the morning of the 5<sup>th</sup> day of the doubled dose, and she was acutely aware upon waking that morning – she hadn’t even gotten out of bed, she had just opened her eyes – that all of her symptoms were gone.

She’s been running around ever since, just as energetically as she had been before she started getting sick. She has put her business back together, she’s back to exercising, she has her old life back. She forgot her dose once about 3 months into this. She got punished for that about 18 hours later when her malaise came back in force. So she quickly took the dose she had missed, and about 12 hours later things settled back down. She has had an occasional incident since then of a mild relapse of malaise. She has learned to just pop an extra Gleevec when that happens and the extra dose reliably, quickly, completely quells the spell. Now, it’s important to understand that what I’m describing to you is, as I’ve learned since this serendipitous first encounter with MCAS,

Mastocytosis Society Canada Medical Lecture – June 6, 2011

Contact: [info@mastocytosis.ca](mailto:info@mastocytosis.ca) or [afrinl@musc.edu](mailto:afrinl@musc.edu)

Systemic Mast Cell Disease: An Update – L. Afrin, M.D., Medical University of South Carolina

an atypical response to Gleevec. I will show you other nice responses to Gleevec, but this one is atypical with respect to how complete the response was.

[Slide 19: Pure Red Cell Aplasia.]

## Pure Red Cell Aplasia

- In 2004 a 53 year old white female presented with worsening fatigue.
- Initial work-up found severe normocytic anemia.
- Further work-up by an academic hematologist found idiopathic pure red cell aplasia, confirmed over time by another academic hematologist and three community hematologists.
- No response to various immunosuppressive therapies and immune globulin.
- Transfused 3 units PRBCs q 2-3 wks to maintain Hgb 6-7

Afrin LB. Pure red cell aplasia masquerading as mast cell activation disorder. *Int J Hematol* 2010 June.

Now, on to virtually a polar opposite case in terms of presentation. This is the 3<sup>rd</sup> patient I diagnosed with MCAS. In 2004 a 53 year old white female presented with worsening fatigue. She was found to have severe anemia, and she was certified by multiple academic and community hematologists as having a pretty rare disease called pure red cell aplasia (PRCA), and furthermore this was a form of PRCA which was not due to parvovirus B19. She had had no response to all the standard therapies for PRCA. She became heavily transfusion dependent.

[Slide 20: Pure Red Cell Aplasia.]

## Pure Red Cell Aplasia

- In 2008 she was referred by her local hematologist for another hematologic opinion.
- Review of systems was extensively positive. A search for a unifying diagnosis was pursued.
- Urinary prostaglandin D<sub>2</sub> was extremely elevated (1,800 ng/24h, normal 100-280).
- H<sub>1</sub> & H<sub>2</sub> blockers immediately resulted in Hgb 8 g/dl and elimination of transfusion requirement.
- Imatinib 200 mg/d resulted in Hgb 13 g/dl in 6 weeks.
- Constitutional symptoms only minimally improved.

Afrin LB. Pure red cell aplasia masquerading as mast cell activation disorder. *Int J Hematol* 2010 June.

Somehow she got referred to me in 2008 for another opinion. And again, a careful history quickly revealed there was no way this could be PRCA because she had a large number of symptoms which could not be explained by PRCA or any of her other known conditions. So it again became a quest for what she could have that had decimated her red cell production and caused all of her other problems. From what I'd been reading about what mast cells are capable of doing, I began to wonder whether it might be possible for one patient to have one variant of mast cell disease that releases mediators which suppress red cell production while another patient has another variant that releases mediators which increase red cell production.

So I did some testing which revealed her to have a very high PGD<sub>2</sub> level which still today is the highest PGD<sub>2</sub> level I've ever seen. I had learned more about treatment by that point, so I did not immediately start her on Gleevec. I started her on antihistamines and immediately eliminated her transfusion requirement, but her hemoglobin persisted around 8 g/dl. I then added low-dose Gleevec, and she had complete normalization of her hemoglobin within 6 weeks. This is actually the first of my MCAS cases that I

Mastocytosis Society Canada Medical Lecture – June 6, 2011

Contact: [info@mastocytosis.ca](mailto:info@mastocytosis.ca) or [afri@muscl.edu](mailto:afri@muscl.edu)

Systemic Mast Cell Disease: An Update – L. Afrin, M.D., Medical University of South Carolina

published, appearing in the *International Journal of Hematology* last summer (2010). Unfortunately, her constitutional symptoms have only been minimally improved. It's clear that Gleevec is not controlling the entirety of the disease, and we continue to search for other means of treatment for her symptoms.

[Slide 21: Opposite presentations, but...]

## Opposite presentations, but...

- ...same root disease?
- How is this possible?
- And, could (many!) other presentations be possible?

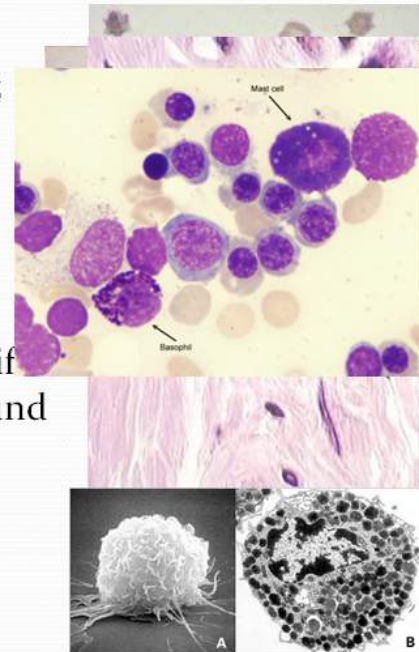
So, opposite presentations (polycythemia and PRCA), but seemingly the same root disease. How is this possible, and is it possible that many other presentations could be out there?



[Slide 22: Mastocytosis: A Brief History.]

## Mastocytosis: A Brief History

- 1869: Urticaria pigmentosa (UP) first described
- 1877: First description of the *mastzelle*
- 1887: UP linked with *mastzelles*
- 1933: Suggestion of linkage with internal dz
- 1939: MC heparin identified
- 1949: Definitive linkage with systemic dz
- 1953: MC histamine identified
- 1987: MC tryptase identified
- 1988: Travis classification
- 1995: KIT activating mutation D816V identified
- 1998: Unique flow cytometric signature found
  - CD117 + (CD25 and/or CD2)
- '90s: Initial descriptions of MCAS
- 2001: WHO classification and imatinib



Let's digress for a moment to the history of mastocytosis.

This is a disease of mast cells that we've known about for the last 140 years. Urticaria pigmentosa was first described in the late 1860's and was linked with the mast cell – a “well-fed” heavily granulated metachromatic cell – described by Paul Ehrlich in the late 1870's. Fifty years later the cell was linked to internal, systemic disease. Then we started finding the mediators that mast cells release – heparin, histamine, tryptase. The first classification of mast cell disease was produced in the late 1980's, shortly followed by identification of the mutation (KIT-D816V) which has now been found in more than 90% of cases of systemic mastocytosis. Just a few years later, Dr. Escribano and colleagues in Spain identified a unique flow cytometric signature – CD117 co-expressed with CD25 or CD2 – that seems to be pathognomonic for mast cell disease. It was actually in the early 1990's in an article by Jack Roberts and John Oates in the *Journal of Investigative Dermatology* where you see the first suggestion of what has come to be called mast cell activation syndrome (MCAS). I'm obviously paraphrasing here, but what they basically said was, “We know there are patients who behave like they have



mast cell disease, and we can find elevation in some mediators in some of these patients, but in other patients we can't find any elevated mediators. Also, we often have a hard time finding the aberrant mast cells themselves (above and beyond finding the abnormal mediator levels). In summary, we think there is a disease here, but we just can't yet characterize it better".

Then in 2001 the first World Health Organization classification of Systemic Mast Cell Diseases was released. That's also the year when Gleevec became available, and we soon learned that the dominant mutation in systemic mastocytosis – the KIT-D816V mutation – by and large is resistant to Gleevec. To be sure, there indeed are some patients with KIT-D816V who respond to Gleevec, and we don't have reasons for that at the moment. But, by and large, imatinib is not going to work for patients with systemic mastocytosis. (However, I'm going to show you some information in a second that there is a whole lot more to mast cell disease than systemic mastocytosis.)

**Dr. Sibbald:** Just out of curiosity, around the room, the other physicians, what have you experienced in terms of mast cell disease? In terms of the spectrum that you've seen? I have a tremendous number of these patients, and I would say that by and large the ones that I see are mostly cutaneous, with some systemic symptoms. There seems to be a big overlap with the physical urticarias manifesting dermatographic and cholinergic responses to heat, exercise, and emotion, and lots of histamine-releasing drugs appear to act as triggers. We don't see too many with the systemic disease, but I'm curious about your perspective.

**Dr. Trinkaus:** A lot of these patients come to us because they have very severe anaphylaxis and constitutional symptoms including overwhelming fatigue, stomach upset, and nausea. So our practice is just exactly what you've been doing except for the urine PGD<sub>2</sub> test. I don't think we have access to that at our hospital, and that's something I plan to look into because in one in seven of the patients we test for mast cell disease, all the tests are negative and this poor patient is just sitting there in diagnostic limbo. Some of them plead for me to "just do something for them," and it's just so overwhelmingly impossible to deal with. And they're on everything. We have had one mast cell leukemia and that person also had the KIT-D816V mutation. We tried Gleevec, but unfortunately he passed away. I probably see one or two mast cell disease patients a month. I only started about 2 years ago, but I see about 3 patients that have legitimate systemic mastocytosis, including one in whom it just spontaneously resolved.

**Dr. Sibbald:** My patients, too, usually have normal tryptase levels.

**Dr. Trinkaus:** Yes, lots of ours have normal tryptase.

**Dr. Afrin:** We'll get to more discussion on that aspect in a moment.

**Dr. Monthropey:** I'm sort of new as a dermatologist, so my first mastocytosis patient was today. At least, I'm pretty sure it's mastocytosis. I sent her for a serum tryptase, and I'm not sure how that's going to come back. I'm wondering if I should have tried to send her for a urinary PGD<sub>2</sub> because I think I think Sunnybrook Hospital may actually be able to do that test (but I'm not sure).

**Dr. Sibbald:** It's not very easy to get the PGD<sub>2</sub> urine test. We can't get them. Marsha?? I don't think I've been able to get any of those.

**Dr. Trinkaus:** Neither can I.

**Dr. Sibbald:** You know, the prostaglandins are so short-lived and require carefully controlled conditions for harvesting and processing. Marsha, your experience in endocrinology?

**Dr. Werb:** Well, actually they come usually looking for a pheochromocytoma or carcinoid, and they come in with very variable symptoms. I'm more used to thinking about glucagonomas when I see the kind of migratory erythematous rash often seen in mast cell disease. But my one or two cases that I'm involved with, as soon as they've been discovered to have mast cell disease, they leave me because they don't have an endocrine disorder, so how they get treated is very interesting to me, especially about Gleevec. You said the KIT-D816V mutation (predicting for resistance to Gleevec) is absent in 10% of these patients?

**Dr. Afrin:** Yes, but that's 10% just in systemic mastocytosis, and I'll be speaking more later about mast cell activation syndrome, which is the far more prevalent problem.

**Shelley:** I'm also interested in this because I have had, and continue to have, endocrine problems, and I also have mastocytosis.

**Dr. Werb:** Thyroid disease, for example, is so common that 20% of women by the time they're 50 will have something wrong with their thyroid, although it may not need to be treated. So many people with urticaria also have autoimmune thyroid disease. It's not surprising that we resort to assigning the patient the obvious diagnosis even if that usually doesn't explain all the symptoms.

**Dr. Monthropey:** I was just going to say that during my residency at Sick Kids Hospital, I saw tiny lesions with mastocytosis, but all these were in little kids in whom we never really did systemic workups on them because we were taught that it's usually cutaneous and it tends to stay cutaneous. Is that true?

**Dr. Afrin:** Cutaneous mastocytosis typically behaves the way you've been taught that cutaneous mastocytosis behaves, including tending to present in childhood rather than adulthood, tending to not evolve into systemic mastocytosis, and not uncommonly

Mastocytosis Society Canada Medical Lecture – June 6, 2011

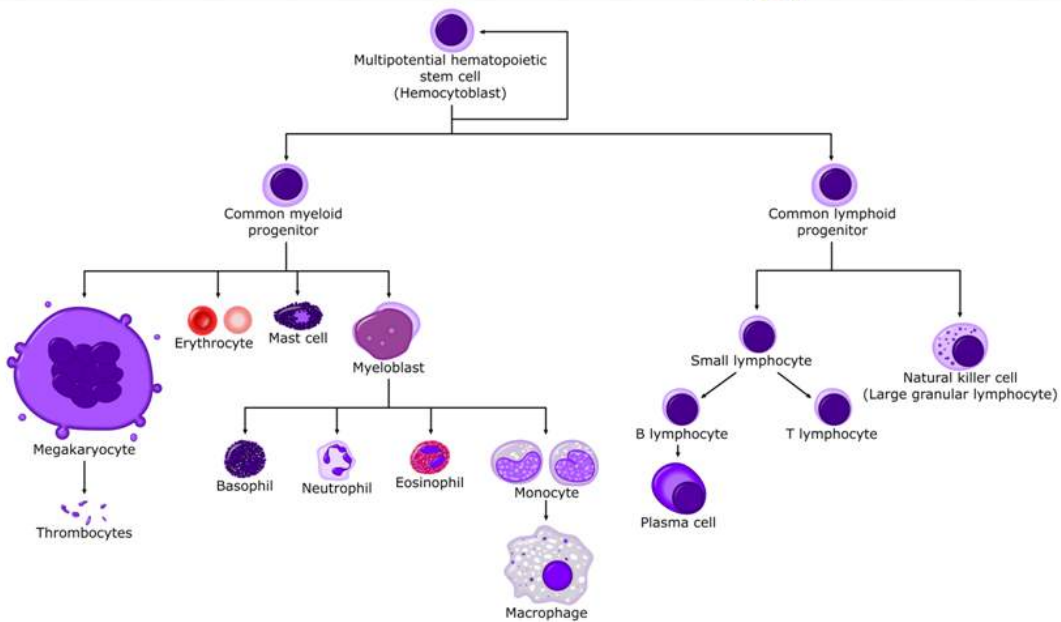
Contact: [info@mastocytosis.ca](mailto:info@mastocytosis.ca) or [afrinl@musc.edu](mailto:afrinl@musc.edu)

Systemic Mast Cell Disease: An Update – L. Afrin, M.D., Medical University of South Carolina

spontaneously resolving in adolescence. Systemic mastocytosis – if it's properly diagnosed according to the WHO criteria – behaves the way you've been taught systemic mastocytosis behaves, but cutaneous and systemic mastocytosis are only a tiny portion of the big picture of mast cell disease, as you'll see better as we keep going through this.

[Slide 23: Normal mast cell biology.]

## Normal mast cell biology



From [allthingsstemcell.com](http://allthingsstemcell.com)

The mast cell is a very primitive cell that differentiates from a common white cell progenitor very early. These are long lived cells that are hard to kill.

[Slide 24: Normal mast cell biology.]

## Normal mast cell biology

- Hematopoietic origin, brief circulation
  - c-kit+/CD34+/FcεRI-/FcγRII+
  - Normally 0.05% of marrow nucleated cells
  - Typically < 2% even in systemic mastocytosis
- Maturation completed in wide distribution of tissues
  - Especially abundant beneath environmentally exposed mucosal/epithelial surfaces and adjacent to blood and lymphatic vessels, permitting sentinel function
  - c-kit+/CD34-/FcεRI+/FcγRII-
- Relatively immobile once localized in peripheral tissue

Kalesnikoff J, Galli SJ. New developments in mast cell biology. *Nature Immunology* 2008;9:1215-1223.

Mast cells are of hematopoietic stem cell origin. They circulate only briefly. They comprise a very small proportion of the marrow cells. They rapidly leave the circulation and enter the peripheral tissues. They are present in every peripheral tissue in the body, where they are relatively immobile and tend to live as long as the patient lives. They are especially abundant at the environmental interfaces, and this is what allows them to perform their evolutionarily critical function as a sentinel. We now believe these may have been some of our first lines of defense to evolve against the toxins in our environment.



[Slide 25: Normal mast cell biology.]

## Normal mast cell biology

- Unique flow signature
  - CD117+ (bright), CD34-, FcεRI+, CD45+, CD38-, CD138-, CD33+, CD13+/-, CD15-, CD16-, CD11c+, CD11b+/-, CD71+, CD25-, and CD2-
  - Also usually CD35+, CD68+
    - Consider mastocytosis in CD68+ histiocytic/macrophage dz's

Escribano L, Diaz-Agustin B, Lopez A, et al. Immunophenotypic Analysis of Mast Cells in Mastocytosis: When and How to Do It. Proposals of the Spanish Network on Mastocytosis (REMA). *Cytometry Part B (Clin Cytometry)* 2004, 58B:1-8.

Mast cells, both normal and abnormal, have a unique flow cytometric signature. These cells are brighter with their cell surface expression of CD117 by an order of magnitude than other cell in the human body. Under normal circumstances, they are always negative for CD25 and CD2. In the abnormal state, they sometimes can co-express CD25 and/or CD2 along with CD117, so if you're going to do a bone marrow biopsy on a patient in whom you clinically suspect mast cell disease, you must send the aspirate for flow cytometry specifically for dual expression of both CD117 and CD25 or CD117 and CD2 and triple expression of CD117, CD25, and CD2.

These cells sometimes are CD68-positive as well. Many pathologists think more about macrophage or histiocyte disease when they see this signature and may not be aware that mast cells can also mark CD68-positive. If you find a patient to have a diagnosis that has been labeled as a histiocytic or macrophage disease, but it's behaving more like a mast cell disease, you may need to go back to that pathology and run the additional testing looking to see if what had been described as macrophages or histiocytes might actually be mast cells.

[Slide 26: Normal mast cell biology.]

## Normal mast cell biology

- Many triggers
  - Classic: Adjacent high-affinity IgE receptors (FcεRI) with bound IgE get crosslinked by polyvalent antigen
  - Physical stimuli: Pressure/trauma, heat, cold, etc.
  - Many other receptors for: SCF, IgG, C3a, C5a, PAF, neuropeptides (VIP, substance P, somatostatin, etc.), opioids, paralytics, benzodiazepines, cannabinoids, etc.
  - Also many of the Toll-like receptors (affinities for various microbial proteins)

Theoharides TC *et al.* Novel therapeutic targets for autism. *Trends Pharmacol Sci* 2008;29:375-382.  
Conrad DH *et al.* Binding parameters of the interaction between rat IgE and rat mast cell receptors. *J Immunol* 1975;114:1688.  
Woolhiser MR *et al.* IgG-dependent activation of human mast cells following up-regulation of FcγRI by IFN-γ. *Eur J Immunol* 2001;31:298.  
Bischoff SC *et al.* c-kit ligand: a unique potentiator of mediator release by human lung mast cells. *J Exp Med* 1992;175:1237.  
Nilsson G *et al.* C3a and C5a are chemotaxins for human mast cells and act through distinct receptors via a pertussis toxin-sensitive signal transduction pathway. *J Immunol* 1996;157:1693.  
Marshall JS *et al.* Toll-like receptor-mediated activation of mast cells: implications for allergic disease? *Int Arch Allergy Immunol* 2003;132:87.  
Church MK *et al.* Neuropeptide-induced secretion from human skin mast cells. *Int Arch Allergy Appl Immunol* 1991;94:310.  
Stellato C *et al.* Heterogeneity of human mast cells and basophils in response to muscle relaxants. *Anesthesiology* 1991;74:1078.  
Moss J *et al.* Histamine release by narcotics and muscle relaxants in humans. *Anesthesiology* 1983;50:330.  
Miller LG *et al.* High affinity benzodiazepine receptors on rat peritoneal mast cells and RBL-1 cells: binding characteristics and effects on granule secretion. *Pharmacology* 1988;36:52-60.  
Samson M-T *et al.* Differential Roles of CB1 and CB2 Cannabinoid Receptors in Mast Cells. *J Immunol* 2003;170:4953-4962.  
Kajiwara N *et al.* Activation of human mast cells through the platelet-activating factor receptor. *J Allergy Clin Immunol* 2010;125:1137.

Mast cells have many triggers, but the classic route to activating a mast cell is mediated through IgE. (I apologize to the non-physicians in the audience that I don't have the time to go into all the details of what that means.) There are many physical stimuli, too, for these cells, such as those listed here, even certain wavelengths of radiation (such as ultraviolet) and electrical stimuli. With virtually every passing month, I am seeing, or hearing about, patients with ever odder physical stimuli for their disease. There are many cell surface receptors beyond just the IgE receptors. Stem cell factor is the ligand for the KIT protein. KIT is the key regulatory gene and protein for the mast cell. We'll get more into that in just a second.

As indicated on this slide, there are lots of other mast cell surface receptors, too, some of which are stimulatory and some of which are inhibitory, all very appropriate given the sentinel function of these cells. These cells have many receptors for different microbial proteins, too.

[Slide 27: Normal mast cell biology.]

## Normal mast cell biology

- Capable of synthesizing and releasing 200+ mediators
  - Many expressed at very high levels
  - Stored in fully active form in electron-dense secretory granules, tightly packaged with serglycin proteoglycans
  - A small sample:
    - **Pro-inflammatory cytokines**
      - IL-1 $\alpha$ , IL-1 $\beta$ , IL-2, IL-4, IL-5, IL-6, IL-7, IL-9, IL-10, IL-12, IL-13, IL-15, IL-16, IL-18, IL-21, IL-23, IL-25, IFN- $\gamma$ , TNF- $\alpha$
    - **Chemokines**
      - MCP-1, IL-8, RANTES, eotaxin, leukotrienes B<sub>4</sub>, C<sub>4</sub>, D<sub>4</sub>, E<sub>4</sub>, (SRS-A), CCL2, CCL3, CCL4, CCL5, CCL11, CCL19, CCL20, CCL21, CXCL8, CXCL10, XCL1
    - **Proteases**
      - Trypsin, chymase, ACE, carboxypeptidase, cathepsin G, cysteinyl cathepsins, metalloproteinases
    - **Growth factors**
      - IL-3, GM-CSF, bFGF, VEGF, TGF- $\beta$ , PDGF, EGF, NGF, SCF, angiopoietin
    - **Vascular permeability, vasodilatation**
      - Histamine, 5-hydroxytryptamine, tryptase, NO, VLA<sub>4</sub>
    - **Platelet aggregation and thrombosis:**
      - PAF, thromboxane
    - Heparin proteoglycan
    - Chondroitin sulfate proteoglycan
    - Superoxide dismutase
    - Acid hydrolases
      - Glucuronidase, galactosidase, hexosaminidase, peroxidase
    - Arylsulphatase A
    - Prostaglandin D<sub>2</sub>, E<sub>2</sub>, F<sub>2 $\alpha$</sub> , thromboxane
    - Serotonin
    - Antimicrobial agents
      - IFN- $\alpha$ , IFN- $\beta$ , IFN- $\gamma$ , cathelicidin, LL-37
    - CRH
    - TSLP

Want more? See <http://www.copewithcytokines.de/cope.cgi?key=mast%20cells>

Theoharides TC et al. Differential release of mast cell mediators and the pathogenesis of inflammation. *Immunological Reviews* 2007;217(1):69-78.

These cells are capable of synthesizing and releasing more than two hundred different mediators and receptors, many of which are expressed at very high levels. I know some of the information on this slide is too small to read, but the point of such an extensive listing is not for you to come to know each mediator in detail but rather to appreciate how extensive the mediator list actually is. This list that you see here is very similar to most every mast cell mediator list you will find in textbooks, on the Internet, etc. This list here is a relatively short list, and even this list doesn't begin to give you a full sense of what these cells are capable of doing. I refer interested colleagues and interested patients to a website called "COPE With Cytokines", built and maintained by German biologist Horst Ibelgaufts. Even the COPE list is not a complete list of all known mast cell mediators and receptors, but I refer people interested in this topic to the COPE list because it nevertheless is the "most complete" list I have yet found in one place. Again, I know it's not a complete list, but if you want to go to just one place to get the best visceral impact as to the full scope of what these cells are capable of doing, this is the site to go to, and when you navigate through this site to get to the entry for "mast cells," you'll see a very, very long list of mediators and receptors these cells can express.



[Slide 28: Normal mast cell biology.]

## Normal mast cell biology

- Functions (when appropriately stimulated):
  - Synthesize active substances
    - Highly heterogeneous mediator content
  - Release contents of preformed granules via exocytosis
  - Phagocytose particulate material including bacteria, erythrocytes, schistosomes, metals, etc.
- KIT stem cell factor receptor and tyrosine kinase (on 4q11-12) is expressed at high levels on the mastocyte surface
  - Critical for many mastocyte functions including survival, differentiation, chemotaxis, and activation

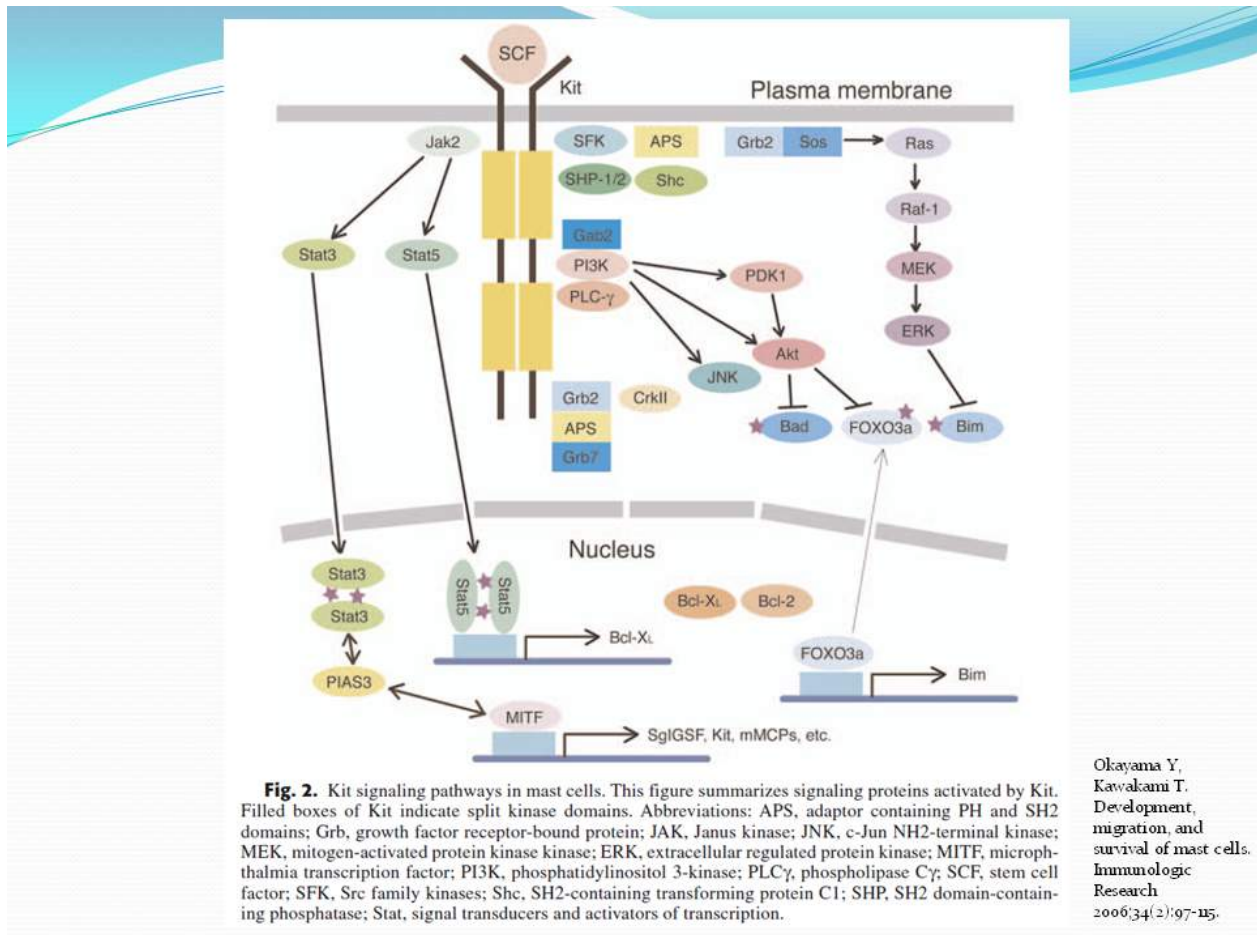
Alan C, Metcalfe DD. The biology of Kit in disease and the application of pharmacogenetics. *J Allergy Clin Immunol* 2004; 114:13-19.

Gordon JR et al. Mast cells as a source of multifunctional cytokines. *Immunol Today* 1990;11:458.

Bradding P et al. Heterogeneity of human mast cells based on cytokine content. *J Immunol* 1995; 155:297.

The mast cell functions to synthesize active substances and to release those substances when stimulated. KIT is the receptor for stem cell factor. KIT is a tyrosine kinase that's expressed in very high levels on the mast cell surface, and it is critical for many mast cell functions including survival and activation.

[Slide 29: Normal mast cell biology.]



This is the obligatory molecular pathway diagram in any hematology/oncology presentation. At the top of the diagram, stem cell factor is binding with a homodimer of KIT. This is the normal pathway. Once KIT is activated, that in turn activates multiple downstream pathways, including the JAK-STAT pathway which leads to the production of various mediators which lead to production of many of the constitutional and other symptoms and findings in this disease. JAK-STAT also factors into cell survival and proliferation as well. It also activates the multiple pathways. The point of this slide is that once KIT is activated, there are multiple downstream pathways that get activated.

**David Girvin:** Before you switch slides, on the plethora of triggers that you had, if you're adding triggers to that slide, would it just be an arrow to KIT?

**Dr. Afrin:** No, because there are plenty of routes for activating mast cells that don't necessarily go through KIT.

**David Girvin:** Thanks.



Mastocytosis Society Canada Medical Lecture – June 6, 2011

Contact: [info@mastocytosis.ca](mailto:info@mastocytosis.ca) or [afrinl@musc.edu](mailto:afrinl@musc.edu)

Systemic Mast Cell Disease: An Update – L. Afrin, M.D., Medical University of South Carolina

**Dr. Afrin:** But what's significant....well....hang on just another couple of slides and you'll see something very interesting, where this biology will really come into play.

[Slide 31: Classification of mastocytosis.]

## Classification of mastocytosis

- WHO '01
  - Cutaneous (usually diagnosed in childhood, 0.01% prevalence)
    - Maculopapular or UP
      - Typical UP, plaque form, nodular form, TMEP
    - Diffuse (occasionally bullous)
    - Solitary mastocytoma of skin
  - Systemic (usually diagnosed in middle age, 0.001% prevalence)
    - Indolent (smoldering vs. isolated marrow)
    - with associated clonal hematologic non-MC lineage disorder (AHNMD)
      - Myelodysplastic, myeloproliferative, or lymphoproliferative
    - Aggressive
      - May feature hepatic fibrosis, portal hypertension, malabsorption, or cytopenias
    - Mast cell leukemia
  - Solid mast cell tumors
    - Mast cell sarcoma
    - Extracutaneous mastocytoma

Valent P, Horny HP, Escribano L, et al. Diagnostic criteria and classification of mastocytosis: A consensus proposal. *Leuk Res* 2001;25:603-625.

The classification back in 2001 that WHO came up with basically lists 3 forms of mastocytosis – the cutaneous form, which is a rare disease usually diagnosed in childhood; the systemic form, which is an even rarer disease usually diagnosed in middle age, and then the extraordinarily rare solid mast cell tumours (which, curiously, actually are seen not infrequently in dogs and cats).

[Slide 32: Criteria for systemic mastocytosis.]

## Criteria for systemic mastocytosis

- WHO '08: Indolent SM, SM-AHNMD, aggressive SM, MC leukemia
  - 1 major + 1 minor, or 3+ minor criteria
  - Only major criterion: “Multifocal, dense aggregates of mast cells (15 or more) in sections of bone marrow and confirmed by tryptase immunohistochemistry or other special stains”
  - 4 minor criteria:
    - More than 25% of the marrow biopsy or aspirate mast cells are immature or atypical
    - Mast cells co-express CD117 with CD25 and/or CD2
    - Mutated c-kit (different mutations → different phenotypes)
      - D816V: MC clusters, spindle forms, expression of CD25, histamine, CPA, etc.
      - Extracellular domain: AKT activation
    - Serum tryptase (25% of MC protein!) persistently > 20 ng/ml

Horný HP, Meccaldi DD, Bennett JM, et al. Mastocytosis. In: Swerdlow SH, Campo E, Harris NL, et al, eds. *WHO Classification of Tumors of Hematopoietic and Lymphoid Tissues (4th ed.)*. Lyon, France: International Agency for Research and Cancer; 2008:54–63.

Mayerhofer M, et al. Unique effects of KIT D816V in BaF3 cells: induction of cluster formation, histamine synthesis, and early mast cell differentiation antigens. *J Immunol* 2008;180:5466–5476.

Teodosio C, et al. Mast cells from different molecular and prognostic subtypes of systemic mastocytosis display distinct immunophenotypes. *J Allergy Clin Immunol* 2010; in press.

Yang Y, et al. Pediatric mastocytosis-associated KIT extracellular domain mutations exhibit different functional and signaling properties compared with KIT phosphotransferase domain mutations. *Blood* 2010 Aug 10; 116(7):1114–1123.

Alvarez-Twose I, et al. Clinical, biological, and molecular characteristics of clonal mast cell disorders presenting with systemic mast cell activation symptoms. *J Allergy Clin Immunol* 2010; in press.

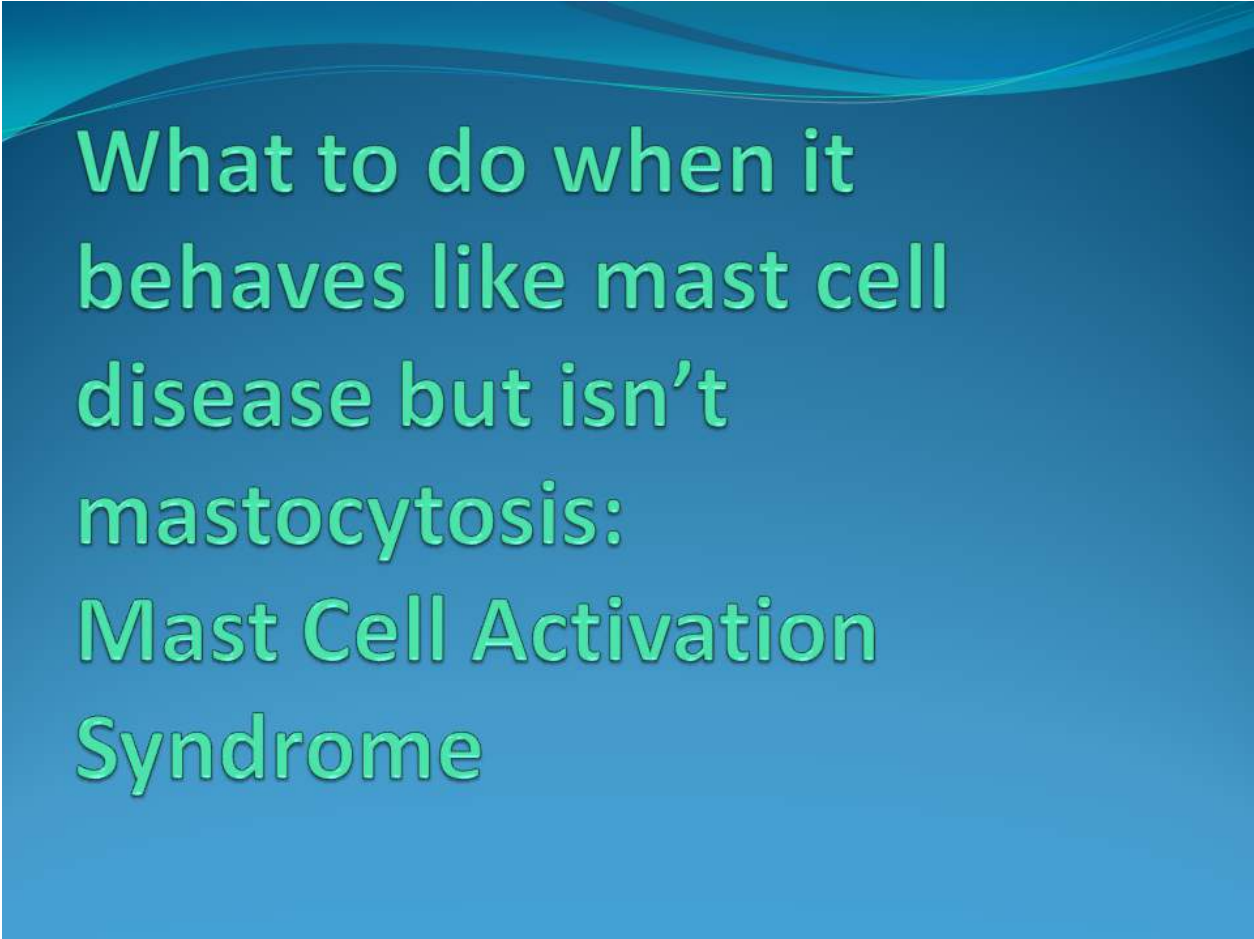
Schwartz LB, et al. Quantitation of histamine, tryptase, and chymase in dispersed human T and TC mast cells. *J Immunol* 2007;178(8):2601–2605.

This was updated in 2008. I'm just going to focus on systemic mastocytosis on this slide. First, we have the form of indolent systemic mastocytosis, which is the vast majority of patients with SM. Second, we have the form in which there is a hematologic non-mast cell lineage disorder (which basically means a blood cancer of some sort, like lymphoma or leukemia) associated with the mast cell disease. It is far more often the case that we recognize the lymphoma or leukemia and don't see the underlying mast cell disease unless it happens to be picked up serendipitously in a bone marrow biopsy. Third, aggressive systemic mastocytosis is the form of the disease in which the cells have actually infiltrated into a given organ (for example, the liver) and are causing significant organ dysfunction. And finally, we have the extremely rare – and, for all intents and purposes, universally rapidly fatal – mast cell leukemia.

Now here is where we get into the biggest problem with the WHO criteria. The WHO criteria say that to get diagnosed with systemic mastocytosis, either you must have one major criterion and at least one minor criterion or you must have 3 or more minor criteria. There's only one major criteria: you must have multi-focal aggregates of mast

cells in the bone marrow. Not in the gut, not in the skin...and you can't just have diffuse low level infiltration of mast cells in the marrow. There have to be aggregates of 15 mast cells or more. I don't envy the pathologist's having to count these cells in a microscopic field of view. The minor criteria are also listed here: serum tryptase has to be roughly double the upper limit of normal on a persistent basis, or more than 25% of the marrow mast cells have to be atypical, or the pathognomonic flow cytometric signature has to be present, or a KIT mutation has to be proven present, but we have very few KIT mutations for which we can commercially test at present.

[Slide 33: The problem.]



# What to do when it behaves like mast cell disease but isn't mastocytosis: Mast Cell Activation Syndrome

So this is the problem: What do you do when it is clinically behaving like systemic mastocytosis, but it doesn't meet the criteria for systemic mastocytosis? For decades now, patients in such a state were denied a diagnosis of not just systemic mastocytosis but mast cell disease in general and often were then discharged by the consultants to whom they were sent for evaluation for mast cell disease. "Sorry, you don't fit the criteria, I don't know what to call you, I don't know what to do with you, and I don't think I can treat you since I can't make a diagnosis since you don't fit the criteria. I'm sorry." But now we do have something we can do for these people. We first of all have a label that we can give them – Mast Cell Activation Syndrome – first suggested back in 1991, as I previously said.



[Slide 34: MCAS: Emerging understanding.]

## MCAS: Emerging Understanding

- First suggested in '91 (Roberts & Oates)
- Emerging consensus definition
  - History consistent with aberrant mast cell mediator release
  - Evidence of aberrant mast cell mediator release
  - ± Evidence of abnormal mast cells
  - Not SM and no better-fitting disease
  - At least partial response to mast cell-targeted therapy
- Terms
  - Mast cell activation disorder/dz
  - Mast cell activation syndrome
  - Systemic monoclonal mast cell activation syndrome

Systemic mastocytosis  
Mast cell activation syndrome  
Monoclonal MCAS

Roberts LJ, Oates JA. Biochemical Diagnosis of Systemic Mast Cell Disorders. *J Invest Derm* 1991 Mar; 96:195-255.

Valent P et al. Standards and standardization in mastocytosis: consensus statements on diagnostics, treatment recommendations and response criteria. *Eur J Clin Invest* 2007;37:435-453.

Homann J et al. Systemic mastocytosis: state of an internal disease. *Medizinische Klinik* 2010;105(8):544-553.

Akin C et al. Mast cell activation syndrome: proposed diagnostic criteria. *J Allergy Clin Immunol* 2010; 126:1099-1104.e4.

There are multiple competing proposals out there in the literature right now for how to define this. There is not a global consensus definition (for MCAS) out there like there is with the WHO definition for systemic mastocytosis. From reading the different papers on this subject in the literature, though, the emerging consensus for diagnosing MCAS appears to be that you have to (1) have a history that's consistent with the disease (i.e., consistent with symptoms and findings expected from persistent or repeated elevations in mast cell mediator levels), (2) have actual laboratory evidence of aberrant mast cell mediator release, (3) not have systemic mastocytosis, (4) not have evidence of other disease that better explains the full range of findings in the patient, and (5) have at least partial response to mast cell target therapy. This last criterion is the controversial one.

Do you have to actually find the abnormal cells? Some earlier proposals said "Yes," but more recent proposals (such as the one by Dr. Cem Akin and colleagues published in the *Journal of Allergy and Clinical Immunology* in December 2010) say "No" because it's just plain hard to find abnormal mast cells in MCAS and it's generally not "worth it" to find the abnormal mast cells. This disease has been ascribed many different terms by

this point, including mast cell activation disorder or disease, mast cell activation syndrome, and systemic non-clonal mast cell activation syndrome (most recently). (“Non-clonal” may be a misnomer, though, as it only implies that the KIT mutations established in systemic mastocytosis are not present. Whole KIT sequencing, currently not routinely commercially available, is beginning to find frequent mutations in other aspects of KIT.) What has come to pass is that “mast cell activation disorder” or “mast cell activation disease” has come to be the umbrella term encompassing all mast cell diseases.

[Slide 35: MCAS: Emerging biology.]

## MCAS: Emerging Biology

- Tryptase usually normal...
  - Correlates more with disease burden than activity
- ...but intermittent or sustained elevations of other mediators almost always present
  - Histamine
  - Prostaglandin D<sub>2</sub>: one of the most sensitive and specific markers of mast cell activation
  - Might heparin be as good as PGD<sub>2</sub>?
  - Other candidates: chymase, carboxypeptidase A (CPA)

Roberts LJ, Oates JA. Biochemical Diagnosis of Systemic Mast Cell Disorders. *J Invest Derm* 1991 Mar; 96:19S-25S.

Brannan JD *et al.* Inhibition of mast cell PGD<sub>2</sub> release protects against mannitol-induced airway narrowing. *Eur Respir J* 2006; 27:944-950.

Bochenek G *et al.* Plasma 9α,10β-PGF<sub>2</sub>, a PGD<sub>2</sub> metabolite, as a sensitive marker of mast cell activation by allergen in bronchial asthma. *Thorax* 2004;59:459-464.

Dahlen S-E, Kumlin M. Mast cell activation: Monitoring mast cell activation by prostaglandin D<sub>2</sub> in vivo. *Thorax* 2004;59:453-455.

Lewis RA *et al.* Prostaglandin D<sub>2</sub> generation after activation of rat and human mast cells with anti-IgE. *J Immunol* 1982; 129(4):1627-1631.

Lixin L *et al.* RasGRP4 Regulates the Expression of Prostaglandin D<sub>2</sub> in Human and Rat Mast Cell Lines. *J Biol Chem* 2003 Feb 14; 278(7):4725-4729.

Zhou X *et al.* Mast cell carboxypeptidase as a new clinical marker for anaphylaxis. *J Allergy Clin Immunol* 2006; 117:S85.

Pejler G *et al.* Mast cell proteases: multifaceted regulators of inflammatory disease. *Blood* 2010 Jun 17; 115(24):4981-4990.

The serum tryptase level is usually normal in MCAS. The level of serum tryptase is now thought by most workers in this field to reflect the total body load of mast cells in most cases of mast cell disease, not the activation state of the mast cell. Thus, since in systemic mastocytosis there is a frank proliferation of mast cells, this is why the serum tryptase level is elevated in more than 80% of cases of systemic mastocytosis. But in MCAS we usually don't see great proliferation, and so the tryptase is typically normal or, in a minority of cases, quite mildly elevated, nowhere close to the cutoff required by the WHO. So tryptase is usually normal in MCAS, but intermittent or sustained elevations in other mediators are almost always present – histamines, PGD<sub>2</sub>, even heparin. Dr. Gerhard Molderings at the University of Bonn in Germany, together with his team, has found that plasma heparin levels are abnormal in more than 90% of patients with mast cell disease, and, for the hematologists in the audience, this is even in spite of the patient's partial thromboplastin time almost always being normal. There are reasons for that, but I'll need to have that discussion later with interested parties. There are other potential candidate mediators for indicating that a state of mast cell activation exists – chymase, carboxypeptidase A (CPA), etc. CPA may be even more sensitive and

Mastocytosis Society Canada Medical Lecture – June 6, 2011

Contact: [info@mastocytosis.ca](mailto:info@mastocytosis.ca) or [afrinl@musc.edu](mailto:afrinl@musc.edu)

Systemic Mast Cell Disease: An Update – L. Afrin, M.D., Medical University of South Carolina

specific than PGD<sub>2</sub>, but there is not presently a commercially available test for CPA. One may become available in about a year or two.

**Dr. Sibbald:** Does MCAS respond to treatments for systemic mastocytosis?

**Dr. Afrin:** Yes. I'll get into more of that later on.

[Slide 36: MCAS: Emerging biology.]

The 3<sup>rd</sup> Most Important Slide In This Presentation

## MCAS: Emerging Biology

- Clonal, but many mutations are being identified
  - More than 50 likely functionally significant mutations scattered across all domains of KIT
  - Most patients have multiple KIT (and other?) mutations
  - No commercial assays yet for most of these mutations
    - Ligand-binding domain: W8R, C12S, del(nt a153), E53K, insertion 71 ?seq(400bp), E73R, T74R, exon 3 & 5 del and ins/del, ins nt 248a, ins Q252, K259E, H265Q, E270K, L276S
    - Dimerization domain: E338K, Q346L, M351E, F355L, E359V, exon 7 ins/del, del (aa 378-390)
    - Proteolytic cleavage site: L416Q, D419H, ins(nt 1282g), exon 8 del
    - Membrane-spanning region: del 510-513, exon 10 ins, M541L
    - Kinase insert sequence K1: S709A, del(S715), A736V, D751Y
    - Kinase domain K2: F782S, N787D, H790R, D816V, S821F, A829T, A837V, L862V
    - C-terminus: complex insertions

Molderings GJ et al. Multiple novel alterations in Kit tyrosine kinase in patients with gastrointestinally pronounced systemic mast cell activation disorder. *Scand J Gastroenterol* 2007; 42(9):1045-1053.

Molderings GJ et al. Comparative analysis of mutation of tyrosine kinase Kit in mast cells from patients with systemic mast cell activation syndrome and healthy subjects. *Immunogenetics* 2010;62:721-727.

What Dr. Molderings discovered back in 2007, and there was a follow-up paper just last summer (2010) confirming and further extending these findings, is that just as systemic mastocytosis is a clonal disease largely of the D816V mutation in KIT, mast cell activation syndrome is a clonal disease, too, but it is a pool of many different clones. There are many different mutations. Dozens of mutations have been found, and they are scattered across all pieces of KIT [slide 37]. Each mutation leads KIT to behave in a different way, driving the cells to produce different aberrant mediator expression patterns leading to different clinical presentations. And it gets worse (with respect to trying to understand MCAS as a single entity): most patients have multiple KIT mutations, and so far there has been little apparent linkage amongst the different mutations. And then there's another twist that makes the situation worse yet: we've also learned that most of these patients also have mutations in other genes and proteins that are integral to mast cell function.

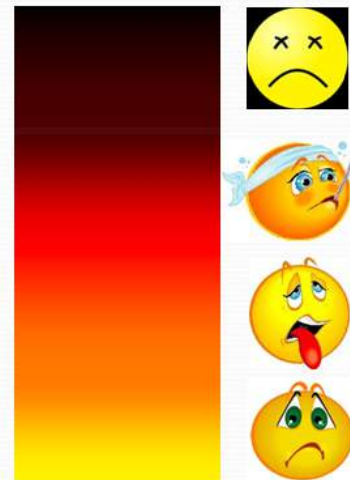

[Slide 38: MCAS: Do the biology math.]

## MCAS: Do the Biology Math

- MCs produce/express >200 mediators
- 1 mutation  $\Rightarrow$  N aberrant mediators
- Multiple KIT mutations in most MCAS patients
- Multiple genes mutated in most MPD patients
- Each mediator has its own unique array of direct and indirect, local and remote effects

Potential for  
Multisystem  
Polymorbidity



So, do the biology math. These cells produce and express dozens of mediators. One mutation leads to aberrant expression of maybe not all mediators in the mast cell but probably a sizable subset. But there are multiple mutations in most patients with mast cell disease including mast cell activation syndrome. How any one mutation might interact with any other one or multiple mutations remains to be determined. And there are multiple genes beyond just KIT that are mutated in most myeloproliferative disease patients. And when you go to that “COPE with Cytokines” website, it will really hit this home for you. Each mediator doesn’t cause just one problem. Each mediator has an entire array, a unique array, of effects – direct effects, indirect effects, local effects, and remote effects – so when you do all the multiplying implicit in all of this biology math, you begin to understand why this disease could present with such extreme heterogeneity.

[Slide 39: MCAS: Presentation]

## MCAS: Presentation

- Typical presentation
  - Age of onset: Any, but often unrecognized for 10+ years if not discovered via childhood urticaria pigmentosa
  - Can affect every system; usually multisystem
  - Symptoms often subtle, chronic-persistent or chronic-intermittent or chronic-waxing/waning
    - Often different symptoms at different times
    - Often no apparent triggers
  - Many physicians
  - Many diagnoses (definitive and/or descriptive)
  - Patients commonly cease reporting symptoms

I'm going to go through a number of slides here running down a sort of a review of systems in patients sprinkled with different case presentations.

In the typical presentation, MCAS could be recognized at any age but often goes unrecognized for more than a decade if not discovered in childhood. It's usually multi-system. The symptoms are often subtle, chronic-persistent or chronic-intermittent, or chronic waxing-and-waning. There are different symptoms at different times. Often there are no apparent triggers, but there also are plenty of patients who very clearly know what their triggers are. Be careful, though, to not think that just because the patient says "I get spells for no reason" that it can't be mast cells. Many of them have no apparent triggers. These patients go through doctors by the trainload. They accumulate large problem lists, and after they figure out, after about 2-3 years of symptoms, that their symptoms aren't going to kill them, and they've learned that no doctor is going to be able to figure out a diagnosis, they stop reporting their symptoms. They may well continue to regularly suffer a wide range of symptoms, but they simply stop volunteering such information to the clinicians they see because such abnormality has become their

new normality. So it really is critical, in trying to clinically detect whether mast cell disease might be present, for the clinician to take the time to take a complete review of systems. I have had patients come to me for various hematologic issues, and I start to pick up a flavour that this could be mast cell disease, leading me to run through a long review of symptoms with them (well beyond the symptoms the referral hematologic issue would be expected to produce). Sometimes when I ask, “Do you ever just pass out?,” I’ve had patients tell me, “Oh, yeah, every other day or so for the last 20 years.” – and they learned 18 years earlier to stop telling their doctors about it because there was no point to telling their doctors about it. They’d already been through a complete workup and had gotten nowhere and their doctors were getting to the point of just thinking they were crazy.

[Slide 40: MCAS: Presentation.]

## MCAS: Presentation

- Constitutional
  - Fever and/or chills (or sense of being cold all the time)
  - Fatigue/malaise (can be disabling)
  - Unprovoked sweats, often nocturnal
  - +/- anorexia and/or early satiety
  - Weight gain (sometimes huge) more common than loss
    - Typically begins subacutely, not associated with identifiable change in diet or exercise
  - Pruritus, often diffusely migratory, sometimes aquagenic
  - Odd and prolific sensitivities (drugs, foods, environs)

The constitutional issues are all over the map, including fevers and/or chills or, most commonly, neither frank fever nor frank chills but rather just a sense of feeling cold all the time. You have to ask about that specifically because if you just ask about fever and chills, they'll often deny both. The fatigue and malaise can be just terrible, to the point of truly utterly disabling the patient. Unprovoked sweats (often, but not always, isolated to the evening and night hours) are another frequent symptom. Some of these patients have anorexia, weight loss, and sometimes early satiety, usually as a result of an enlarging spleen. Much more commonly, though, we see issues not with weight loss but rather with weight gain, sometimes hugely so. I've had a number of these patients come to me after a gastric bypass which did help them lose weight but didn't address any of the myriad of symptoms they had before the gastric bypass which the surgeon never realized or chose not to address prior to surgery in spite of the much greater likelihood of there being a common problem underlying both the obesity and the plethora of other symptoms.

The pruritis can be anywhere on the scale from non-existent to atrocious. Also, these patients not uncommonly have odd allergies such as things you wouldn't think it's possible to be allergic to such as acetaminophen, levothyroxine, aspirin, loratadine, and so forth. The clinician working in this area also has to keep in mind the possibility that what the patient is reacting to is not the active ingredient but rather a filler, and sometimes simply switching to an alternative formulation of the "same" medication can eliminate or reduce many symptoms.



[Slides 41-42: Case: It's a miserable life (#1).]

## Case: It's A Miserable Life (#1)

- A 69 year old woman was referred for chronic mild leukocytosis. PMH/ROS found problems dating to childhood including constipation, refractory onychomycosis, frequent other skin lesions and infections, fatigue, fibromyalgia, emotional lability, G5 with two miscarriages and three low-birthweight deliveries, refractory pruritus and GERD since her 40s, fevers, chills, sweats, presyncope, hunger, headaches, insomnia, cognitive dysfunction, sensory neuropathy, eye/nose/mouth/lip/throat irritation, dyspnea, palpitations, edema, dysuria, cervical adenopathy.

## Case: It's A Miserable Life (#1)

- Tryptase, histamine, uPGD<sub>2</sub>/NMH, and random marrow and GI tract biopsies all normal.
- Serum chromogranin A: 3500 ng/ml (normal 0-50).
- High-dose histamine blockade worsened many problems; low-dose blockade immediately resolved throat soreness and cervical adenopathy.
- Intolerant of aspirin, montelukast, nebulized and oral cromolyn.
- Lorazepam 0.25-0.5 mg t.i.d. and zolpidem 10 mg qhs immediately resolved virtually all symptoms.

A 69 year old woman was referred for chronic mild elevated white count. I'm not going to go through all the details; suffice to say there was a boatload of problems she had had for decades, going all the way back to childhood. Initial screens for mast cell disease were all negative except her serum chromogranin A level was stratospheric. Most physicians, by their classic training, will tell you a situation like this has to be a neuroendocrine cancer, except cancer patients look and behave in a certain way, and though she was chronically sick to be sure, she didn't look anything like "cancer sick." So there had to be another source for the chromogranin A. Heart and renal failure and proton pump inhibitor use can elevate chromogranin A levels modestly, but nowhere near the levels seen in this patient. Interestingly, when you go digging into the list of mediators the mast cell can elaborate, you quickly come across chromogranin A. So, besides a neuroendocrine cancer that she didn't have and a mast cell disease that fit her chronic multisystem polymorbidity perfectly, there was no other possible source for the chromogranin A. This had to be mast cell disease. High dose histamine blockade curiously worsened many of her problems (perhaps a filler issue?), but the low dose blockade (possibly with a different formulation?) immediately helped in a number of areas. She was intolerant of a number of other cheap treatments, so then we decided to try simple old lorazepam in combination with zolpidem, which is not a benzodiazepine

Mastocytosis Society Canada Medical Lecture – June 6, 2011

Contact: [info@mastocytosis.ca](mailto:info@mastocytosis.ca) or [afrinl@musc.edu](mailto:afrinl@musc.edu)

Systemic Mast Cell Disease: An Update – L. Afrin, M.D., Medical University of South Carolina

like lorazepam but nevertheless targets the benzodiazepine receptor. And those two simple little drugs turned off about 95% of her symptoms. At age 69 she was a new woman.

[Slides 43-44: Case: It's a miserable life (#2)]

## Case: It's A Miserable Life (#2)

- An adolescent girl had menarche at 16. Subsequent problems through adulthood included diffuse/migratory/waxing/waning arthritis, HTN, hyperlipidemia, GERD, premature menopause at 38, resected lung cancer and CABG at 59, ischemic colitis at 63 associated with onset of sweats and panic attacks, presyncope since 65, intense pruritus since 71.
- ROS also positive for chronic/episodic/waxing/waning eye irritation, dyspnea, non-anginal chest pain, palpitations, breast soreness and fibrocystic disease, dysphagia, constipation, dysuria, edema, hearing deficits.

## Case: It's A Miserable Life (#2)

- Local investigation found mild anemia and leukopenia and elevated tryptase (34 ng/mL).
- Marrow examination negative.
- Refractory to all anti-pruritics, referred at age 73.
- Gastric biopsy taken at 71 re-examined; increased mast cells found on immunohistochemistry.
- Histamine blockers resolved sweats and eye irritation.
- Intolerant of aspirin, montelukast, oral cromolyn.
- All remaining symptoms resolved with dasatinib 20 mg/d.

An adolescent girl had delayed menarche at age 16 and many subsequent problems throughout adulthood included not only a first boatload of issues she spontaneously reported when initially seeing me in referral at age 71 but also a second boatload of issues that emerged on a full review of systems. Investigation by her local physicians had found mild anemia, a low white count, and tryptase that was elevated into the range that satisfies the minor diagnostic criterion for systemic mastocytosis, but the marrow was completely negative including the special flow cytometric testing. What do you do? She clearly does not meet the criteria for systemic mastocytosis. She was actually referred to me for refractory severe pruritis. She had been tried on everything. Nothing was helping her with the itching that was destroying her life. I went back to a gastric biopsy she had had done for one of her GI complaints two years earlier, restained it with the right immunohistochemistry – and there was the mast cell disease. Histamine blockers helped only a little bit. She was intolerant of several other drugs. I finally got around to trying her on very-low-dose dasatinib, and it just turned everything off. For her disease it was the right switch, a molecular switch.



[Slide 45: MCAS: Presentation]

## MCAS: Presentation

- Ophthalmologic
  - Irritated (dry, sandy) eyes
  - Lacrimation
  - Pruritus
  - Suffusion
  - Conjunctivitis
  - Inability to focus
  - Lid tremor/tic
  - Intermittent infection or sterile inflammation

The ophthalmologic issues are all over the map. Irritated eyes, gritty, sandy, dry...you have to use all these words in going through a review of symptoms because they will deny many adjectives but finally acknowledge the one that you hit on. It all boils down to various flavours of inflammation which is usually sterile, but because of the impact the disease has on the immune system, infectious problems can easily arise, so you do have to remain alert to the occasional true infections these patients can have.

[Slide 46: MCAS: Presentation]

## MCAS: Presentation

- Otologic
  - Intermittent infections or sterile inflammation
  - Hearing deficit or tinnitus
  - Otosclerosis

The same sterile or infectious inflammatory issues that arise with the eyes in MCAS can arise in every other system in the body, too, including the ears, where they can present with present waxing and waning tinnitus (a ringing in the ears), hearing deficits, and otosclerosis. I've seen MCAS in several patients now, too, who became idiopathically deaf during childhood or adolescence, and I think I can be forgiven for wondering whether MCAS was the cause of that problem, too.

[Slide 47: MCAS: Presentation]

## MCAS: Presentation

- Oral/oropharyngeal
  - Pain (often “burning”)
  - Leukoplakia
  - Fibrosis
  - Lichen planus
  - Throat discomfort/irritation/tickle leading to intermittent dry cough and/or proximal dysphagia

Afrin LB. Burning Mouth Syndrome and Mast Cell Activation Disorder. *Oral Surg Oral Med Oral Path Endodontology* 2011;111(4):465-472.

Oral issues in MCAS are frequent, especially diffuse pain in the mouth that’s often described as a burning. They’ll deny quite often a soreness or irritation in the throat, but if you ask them, “Do you have this ongoing sense of a need to clear your throat, a tickle in your throat that leads to a chronic cough or a chronic throat clearing?,” that’s a symptom they will often acknowledge, and it’s a low grade inflammation of the pharynx.

[Slides 48-50: Case: Burning mouth syndrome.]

## Case: Burning Mouth Syndrome

- In 2004 a previously fairly healthy 54 year old woman acutely developed a persistent sensation of burning throughout the mucosa of the entire GI tract, worse by far (pain 10/10) in the mouth.
- Extensive evaluation by specialists in internal medicine, oral surgery, ENT, GI, infectious disease, and rheumatology were unrevealing except for biopsy showing mild chronic gastritis and, eventually, discovery of a 100-fold elevated serum chromogranin A
- Hematology/oncology was consulted

Afrin LB. Burning Mouth Syndrome and Mast Cell Activation Disorder. *Oral Surg Oral Med Oral Path Endodontology* 2011;111(4):465-472.

## Case: Burning Mouth Syndrome

- Extensive searching for neuroendocrine cancer (although she didn't look like she had such) was fruitlessly pursued.
- The top five U.S. neuroendocrine cancer experts were consulted by phone; all were absolutely confident she must have a neuroendocrine cancer and recommended periodic repeat testing, especially advanced imaging.
- Evaluation for mast cell disease found negative tryptase and plasma and urinary histamine and PGD<sub>2</sub>.
- Two marrow biopsies, two oral mucosa biopsies all nl.

Afrin LB. Burning Mouth Syndrome and Mast Cell Activation Disorder. *Oral Surg Oral Med Oral Path Endodontology* 2011;111(4):465-472.



## Case: Burning Mouth Syndrome

- Four years after symptoms began, immunohistochemical staining of the gastric biopsy showing gastritis revealed substantially increased mast cells.
- Antihistamines and NSAIDs reduced her pain to 1/10 overnight. Response has been sustained two years.
- Five other patients with BMS now evaluated:
  - Different aberrant mediator expression patterns
  - All with increased mast cells in GI tract biopsies
  - All responding to various mast-cell-targeted therapies

Afrin LB. Burning Mouth Syndrome and Mast Cell Activation Disorder. *Oral Surg Oral Med Oral Path Endodontology* 2011;111(4):465-472.

There actually is a syndrome in the medical literature, primarily in the oral literature, which I certainly never heard about until the middle of the last decade, called burning mouth syndrome. In 1990 a U.S. National Institutes of Health survey found 1% of everybody in the U.S. complains of a chronically burning mouth. Who knew? I didn't. Nevertheless, it's there, and in some people it can be severe enough to require medical attention (though often to little avail).

In 2004 a previously fairly healthy 54 year old woman acutely developed persistent burning throughout the mucosa of the entire GI tract, worse by far in the mouth. She consistently described the pain as 11 out of 10. From the moment she woke up in the morning to the moment she finally exhaustedly fell asleep each night, she was in severe oral pain. Extensive evaluations (including multiple oral mucosa biopsies) were all negative except biopsy of the stomach showed mild chronic gastritis. Multiple types of pain relievers were unhelpful. Nine months after initial onset of her burning mouth pain, she was found by an enterprising gastroenterologist to have a 100-fold elevation in her serum chromogranin A. This is actually the second patient in whom I diagnosed MCAS, just a couple months after my index case of MCAS-induced polycythemia we discussed earlier. The gastroenterologist referred this patient to oncology, saying she had to have

a neuroendocrine cancer. When I initially saw her, she certainly looked chronically ill, but, again, she didn't look "cancer sick." There was just no way she had cancer, yet at that time I didn't know any other disease that could produce a serum chromogranin A level that starkly elevated. So I did my duty as an oncologist and went looking for a neuroendocrine cancer. Starting in 2005 (three years before my index case of MCAS-induced polycythemia), I looked – repeatedly – really hard for her neuroendocrine cancer and just could not find any trace of such a thing beyond the chromogranin level. I called the top 5 neuroendocrine cancer experts in the country, and they all praised how thorough I had been in looking for the neuroendocrine cancer, and they unanimously concluded, "You just have to keep looking because it has to be a neuroendocrine cancer." Around the time I made my index diagnosis of MCAS-induced polycythemia, I began to wonder whether mast cell disease could be causing the burning mouth syndrome here, so I evaluated her for this. It was all negative. Two marrow biopsies and two oral mucosa biopsies, all negative. And then I went back to the old GI biopsies, had the pathologist do the appropriate immunohistochemistry for mast cell disease, and there it was. Antihistamines and non-steroidal anti-inflammatories together reduced her pain overnight from 11/10 to 1/10. She has done well for the last two years. I have now found MCAS underlying burning mouth syndrome in several other patients, and in April 2011 I published in one of the oral medicine journals my first 3 cases of this. Since that was written, though, I've now found another 3 patients with this. I'm not trying to say that all cases of burning mouth syndrome are actually MCAS. There are cases of burning mouth syndrome that are caused by Sjögren's disease, candidiasis, or other causes, but there's an awfully large fraction where the cause is utterly unknown and every study imaginable of the mouth finds nothing. All the routine biochemical labs – the blood counts, the chemistries – are all normal, and it is very frustrating for the oral pathologists, the oral surgeons, and the dentists who manage these patients, because they don't know what to tell the patients. They can't find anything wrong, and yet these patients keep coming in over and over again reporting constant severe mouth pain. Well, now we know one additional (and treatable) entity – MCAS – that can cause this.

**Dr. Monthropey:** Just a question...we're taught that NSAIDs degranulate mast cells, making things worse. How can they be effective therapy?

**Dr. Afrin:** They certainly can make things worse for some patients, and then clearly for other patients they can be inhibitory, though the doses required typically are beyond what most physicians are used to using.

**Dr. Sibbald:** NSAIDs can be dangerous in mast cell disease. Before we had some of the better long-acting non-sedating H<sub>1</sub> antihistamines, we used to exercise people to deplete their histamine, and often they would clinically improve just through exercising 2-4 times a day.

**Dr. Afrin:** Of note, the other burning mouth syndrome patients I've found had elevations in mast cell mediators other than chromogranin A and have responded to different

therapies than what worked in my first such patient. I'm not saying that chromogranin A causes the burning sensation or that antihistamines and NSAIDs are the answer to burning mouth syndrome. Different patients have different mutations leading to different mediator expression patterns leading to different assortments of symptoms, and therefore they're going to require different therapies. Clearly, different mediators can lead ultimately to different symptoms, so just because two MCAS patients share a symptom, that doesn't begin to tell you which mediator or combination of mediators is causing it in either patient. My first burning mouth syndrome patient had sky-high chromogranin A levels, but the next five had normal such levels, so it's clearly not the chromogranin A that's causing the symptom. Chromogranin A was just a marker for what was going on in my first burning mouth syndrome patient. I still don't know what the mediators are which were causing her pain.

[Slide 51: MCAS: Presentation.]

## MCAS: Presentation

- Nodal
  - Occasional adenopathy (sometimes tender)
  - Left upper quadrant (splenic?) discomfort not uncommon
  - Pathologically, usually just a reactive lymphocytosis, sometimes an atypical non-specific lymphoproliferative disorder

The nodal issues tend not to be bad. There's occasional adenopathy. Sometimes it's tender, and sometimes there is modest waxing and waning discomfort, particularly in the left upper abdominal quadrant. If you go to the trouble of obtaining biopsies from enlarged and/or tender nodes in MCAS patients, it usually will show only a reactive lymphocytosis. Sometimes the pathologist will go as far as calling it an atypical lymphoproliferative disorder, but he won't commit to calling it a lymphoma, and even though cytogenetic studies may sometimes identify clear clonal abnormalities consistent with lymphoma, it usually won't behave as a lymphoma would be expected to behave.

[Slide 52-53: Idiopathic splenomegaly.]

## Case: Idiopathic Splenomegaly

- In 2008 an airline pilot developed acute “food poisoning”
- Symptoms, including prominent left upper quadrant discomfort, had only partially abated after a month
- Disqualified from piloting
- Local evaluations by internal medicine, infectious disease, hematology/oncology, gastroenterology, and rheumatology were all unrevealing except for idiopathic mild splenomegaly (on imaging only)
- Referred for second hem/onc opinion



## Case: Idiopathic Splenomegaly

- Physical and marrow exams unrevealing.
- Mast cell mediator screening positive only for mild elevation of uPGD<sub>2</sub>
- Moderately improved with antihistamines, NSAIDs, cromolyn, and dasatinib; no improvement with montelukast or imatinib.
- Still too symptomatic to pilot; working part-time customer service at a retail store.

In 2005, an airline pilot in his early 50's developed "acute food poisoning." A lot of MCAS patients will present with that. Not that they haven't had symptoms attributable to MCAS going on for decades, but "food poisoning" sometimes will be their acute presentation. And as will happen with this disease, the food poisoning, if that's what it was, doesn't go away. True food poisoning virtually always goes away, and pretty quickly at that. After a month, his symptoms only partially abated and he was disqualified from piloting, with multiple evaluations all unrevealing except for a tiny bit of enlargement of the spleen for which he got referred to me. Physical and marrow exams were unrevealing, he had a mild elevation of urinary PGD<sub>2</sub>, and he has moderately improved with several drugs as you see (in the slides). He's doing a good bit better now, but he's clearly still too symptomatic to be put back in charge of a commercial airliner. I don't want to give anyone the impression that all of my patients are unqualified treatment successes, because they're not. This patient is now working part-time in customer service at a retail store. That's unfortunate, but it's the reality.

[Slide 54: MCAS: Presentation]

## MCAS: Presentation

- Pulmonary
  - Nasal congestion
  - Rhinorrhea
  - Laryngeal edema/inflammation
  - Hoarseness
  - Cough (usually dry)
  - Dyspnea
  - Cyanosis
  - Wheezing/asthma
    - PGD<sub>2</sub> triggers asthmatic spells
  - COPD? IPF?
    - Mast cells may be effector cells

Matsuoka T *et al.* Prostaglandin D<sub>2</sub> as a Mediator of Allergic Asthma. *Science* 2000 Mar 17; 287(5460):2013-2017.

Bochenek G *et al.* Plasma 9α,11β-PGF<sub>2</sub> a PGD<sub>2</sub> metabolite, as a sensitive marker of mast cell activation by allergen in bronchial asthma. *Thorax* 2004;59:459-464.

Edwards ST *et al.* c-Kit immunophenotyping and metalloproteinase expression profiles of mast cells in interstitial lung diseases. *J Pathol* 2005; 206(3):279-290.

There's a broad range of pulmonary issues that can be seen in MCAS, but what these patients will most commonly complain about in the pulmonary area is something they struggle to find the words to describe. You have to give them the time to figure out how to tell you this, but what they will say in the end is "I just can't get a really deep breath any longer". Extensive pulmonary function testing will be normal, and they'll still tell you, "There is something wrong with my breathing".

[Slide 55: MCAS: Presentation]

## MCAS: Presentation

- Cardiovascular
  - Presyncopal or syncopal spells
    - “Lightheadedness,” “Dizziness,” “Weakness,” “Vertigo,” “POTS”
    - Often no identifiable trigger
  - Hypertension and/or hypotension, sometimes quite labile
    - PGD<sub>2</sub>-induced vasoconstriction is 5- to 10-fold more potent than norepinephrine
  - Palpitations/arrhythmias
  - Typical and atypical “angina,” often without identifiable significant coronary atherosclerosis
  - Aggressive atherosclerosis, aneurysms, hemorrhoids
  - Episodic migratory edema, often labeled CHF in spite of objectively normal heart function

Nagoshi H *et al.* Prostaglandin D<sub>2</sub> Inhibits Inducible Nitric Oxide Synthase Expression in Rat Vascular Smooth Muscle Cells. *Circ Res* 100:8:821-824-2007.

Atkinson JB *et al.* The association of mast cells and atherosclerosis: A morphologic study of early atherosclerotic lesions in young people. *Human Pathol* 100:4 Feb:251-254-1991.

Forman MB *et al.* Increased adventitial mast cells in a patient with coronary vasospasm. *N Engl J Med* 100:8:332-333-1979.

There’s a broad range of cardiovascular issues, too. Pre-syncopal and syncopal spells are common, but few patients will use that terminology. They’ll use lots of different words – “lightheadedness,” “dizziness,” “weakness,” or “vertigo,” and POTS (postural orthostatic tachycardia syndrome) is a very common item on their long problem lists – but if you take a careful history, you will find that some of the POTS spells are orthostatic but many are very clearly not orthostatic. There’s often no identifiable trigger. MCAS patients often have both hypertension and hypotension, sometimes quite labile. Palpitations are common. They can have typical and atypical bouts of chest pain that can send them to the emergency room quite frequently, but if they get to the point of being catheterized, you typically find nothing. On the other hand, some of these folks can manifest extremely aggressive atherosclerosis as well as other vascular anomalies that have clearly been linked to mast cell disease, and they will often tell you about this strange pattern of edema – swelling – that’s a migratory pattern. It doesn’t behave the way heart failure edema behaves and yet these patients, because they complained of swelling, they often get labeled as having heart failure even though they have objectively normal heart function. But heart failure edema doesn’t show up as migratory edema.

[Slides 56-58: Case: First, Do No Harm.]

## Case: First, Do No Harm

- In 1976 a 13 year old boy acutely developed marked fevers, sweats, palpitations, adenopathy, splenomegaly, fatigue/malaise, and diffuse migratory aching and rash
- Extensive evaluation by multiple academic specialists, including careful pathology evaluation of the splenectomy specimen, was unrevealing.
- He improved somewhat, but waxing/waning symptoms persisted.
- At age 30 he suffered his first “heart attack.”



## Case: First, Do No Harm

- By age 48 he had suffered >20 “heart attacks” and “strokes,” though no evidence of coronary or carotid occlusion was ever found except within the stents that were eventually placed by frustrated cardiologists
- In 2008 he was referred for hem/onc opinion for possible hypercoagulability.
- Extensive evaluation for a defined hypercoagulable syndrome was negative.
- Screening for mast cell disease was negative except for significantly increased mast cells on duodenal biopsy.



## Case: First, Do No Harm

- His symptoms proved refractory to antihistamines, NSAIDs, montelukast, benzodiazepines, inhaled and oral cromolyn, imatinib, and dasatinib.
- Rash biopsy appeared consistent with angioimmunoblastic T-cell lymphoma (rash had waxed/waned since initial onset of disease)
- CHOP + denileukin difitox x 1 cycle at age 48 yielded minimal improvement and was then stopped due to concerns regarding accuracy of diagnosis
- Patient died at age 50 of sudden cardiac death

In 1976 a 13 year old boy acutely developed marked fever, sweats, palpitations, adenopathy, an enlarged spleen, disabling malaise, diffuse migratory aching, and rash. Extensive evaluation couldn't find any cause. No diagnosis emerged from pathologic analysis of the spleen when it was removed. He continued to have waxing and waning symptoms. At age 30 he suffered his first heart attack, even though catheterization was clean. By 18 years later he had suffered more than 20 "heart attacks" and "strokes," though no evidence of coronary or carotid artery occlusions was ever found except within the coronary stents that his cardiologist had eventually placed out of frustration. Only After stent placement began did he start having definite obstructions, and all of them were in the stents. He was referred to me in 2008. I looked hard for any known hypercoagulable syndrome and could not find one. Screening for mast cell disease was negative except on duodenal biopsy – clearly substantially increased mast cells. Unfortunately he proved refractory to treatment. I'll skip over the details of this. I really was never able to help this patient, and last year at age 50 he died of sudden heart death, probably as a result of occlusion in one of the stents that had been placed by his well-meaning and understandably frustrated cardiologist.

[Slide 59: MCAS: Presentation]

## MCAS: Presentation

- GI
  - Pain/discomfort/inflammation of any or all segments including luminal tract and solid organs
  - “Refractory GERD” and “IBS” very common
    - Non-ulcerative dyspepsia often responds well to H<sub>1</sub> antagonists
  - Queasiness, nausea, vomiting
  - Diarrhea and/or constipation
  - Malabsorption common (up to a third of cases), either:
    - General protein/calorie, or
    - Any selected micronutrient(s) (e.g., iron, copper, B<sub>6</sub>, etc.)

He S-H. Key role of mast cells and their major secretory products in inflammatory bowel disease. *World J Gastroenterol* 2004;10(3):309-318.

The GI issues again follow on the inflammatory theme in MCAS – pain, discomfort, and inflammation of any or all segments including the luminal tract and solid organs. Refractory GERD and irritable bowel syndrome or inflammatory bowel syndrome are very common. Let me ask you something about refractory GERD patients. These patients are on maximal acid suppression, and yet they continue to complain of a gastritic type of discomfort and reflux. Where is the discomfort coming from if they have no significant acid any longer? My thought is that it never was acid that was causing their problems. They're feeling inflammation. Inflammation hurts regardless of its cause, and though excess acid can be such a cause, in the case of these patients, the inflammation is coming from the release of inflammatory mediators by the mast cell disease. These patients have always had biopsies done, and if you go back to those biopsies and stain them appropriately, you'll likely find histologic evidence of the disease.

Chronic diarrhea (often alternating with constipation) is a common complaint in MCAS and often frustrates their primary doctors, leading them to not uncommonly label the

patients as crazy since, on the surface of it, it would seem there's no way a disease could cause both diarrhea and constipation. Malabsorption, too, is not uncommon, either a general protein-calorie malabsorption that's fairly rare or, much more commonly, there is selective micronutrient absorption deficiency (where the particular micronutrient that's malabsorbed just depends on which mediators are being aberrantly expressed), and if it gets severe enough, the patient then goes on to have the clinical consequences of that micronutrient deficiency which just further complicates the clinical presentation.

[Slides 60-61: Case: It's a Miserable Life (#3).]

## Case: It's A Miserable Life (#3)

- A 56 year old woman was referred for further evaluation of refractory iron-deficiency anemia.
- Her first delivery, at age 18, brought on chronic (and sometimes syncopal) migraines. Pregnancy at 22 required multiple hospitalizations. Miscarried at 23. Constant menorrhagia by 34, TAH/BSO at 35 with ensuing constant exhaustion, mental fog, whole back pain (multiple unhelpful surgeries), presyncope, fevers, sweats, pruritus, throat irritation, dyspnea, edema, IBS, sensory neuropathy, rash, hypothyroidism, hypertension, hyperlipidemia, asthma, colitis, parotiditis, and allergic to “everything.”



## Case: It's A Miserable Life (#3)

- Worsening microcytic anemia since 2009 with no identifiable GI/GU bleeding and no response to oral iron.
- Marked increases in plasma norepinephrine, dopamine, and urinary normetanephrine; mild increase in chromogranin A. No other evidence of pheochromocytoma.
- Substantially increased duodenal and colonic mast cells.
- No response to antihistamines, aspirin, cromolyn, imatinib.
- Immediate complete response to dasatinib 20 mg/d.

A 56 year old woman was referred for further evaluation of refractory iron-deficiency anemia. Her first pregnancy at age 18 brought on a number of obstetric complications and chronic migraines, and many other problems developed over the years since, including eventually becoming allergic to seemingly everything. She then was noted to develop worsening microcytic anemia since 2009 with no identifiable bleeding. An oral iron absorption test showed deficient absorption. She also had marked increases in catecholamines in the blood and urine, mild increase in serum chromogranin A, no evidence of pheochromocytoma or carcinoid, and substantially increased GI mast cells. She had no response to a number of agents we tried initially, but then we put her on low-dose dasatinib and – I am not making this up – she literally danced into the exam room in my clinic for her next checkup. Her improvement has been sustained for several months now. She actually does have one side effect from the dasatinib. She has had a mild headache from it, and I'm trying to deal with that. I'm trying to figure out how can I get her on an even lower dose of dasatinib. They don't make a dose any lower than what she's on, and I can't find a pharmacist who is willing to cut such a tiny, expensive pill. So I'm not quite sure how to solve her dasatinib headache problem, but I guess that's not too big a problem at this point compared to all her trouble previously



[Slide 62: MCAS: Presentation.]

## MCAS: Presentation

- Hepatic involvement in about 50% of cases
  - Fibrosis (obliterative portal venopathy) is the most common pathologic finding
  - Also: fatty metamorphosis, sinusoidal dilatation, venoocclusive disease, nodular regenerative hyperplasia, cirrhosis
  - Inflammation usually mild
  - Cholestasis, portal hypertension uncommon
- Mild elevations in LFTs not uncommon

Alfter K et al. New aspects of liver abnormalities as part of the systemic mast cell activation syndrome. *Liver International* 29(2):181-186.

Hepatic issues in general are common, but what you'll see most commonly in this area by far is just a mild elevation in one transaminase and/or the other, often also with a mild elevation in alkaline phosphatase without an elevation in the bilirubin. This is a pattern often seen with "metabolic syndrome." Nobody knows what causes "metabolic syndrome," and I have been wondering whether "metabolic syndrome," too, might be another presentation of MCAS.

[Slide 63: MCAS: Presentation.]

## MCAS: Presentation

- GU
  - Pain/discomfort/inflammation of any or all segments of the GU tract
  - Infections and/or sterile inflammation
    - e.g., “interstitial cystitis”
  - ESRD? Renal fibrosis?
  - Decreased libido
  - Infertility
    - 15d-PGJ<sub>2</sub> can generate/maintain fibrosis in the tubular wall of the testis
    - Mast cell blockers can treat oligospermia and result in pregnancy

Sant G *et al.* The Mast Cell in Interstitial Cystitis: Role in Pathophysiology and Pathogenesis. *Urology* 2009; 69(4):S34-S40.  
Theoharides TC *et al.* Activation of bladder mast cells in interstitial cystitis: a light and electron microscopic study. *J Urol* 1995; 153:629-636.  
Rudick CN *et al.* Mast Cell-Derived Histamine Mediates Cystitis Pain. *PLoS ONE* 2008; 3(5): e2096.  
Hironuma K *et al.* Tubulointerstitial mast cell infiltration in glomerulonephritis. *Am J Kidney Dis* 1998; 32:593-599.  
Kondo S *et al.* Role of mast cell tryptase in renal interstitial fibrosis. *J Am Soc Nephrol* 2001; 12:1668-1676.  
Frungeri MB *et al.* Sources and functions of prostaglandins in the testis: evidence for their relevance in male (in) fertility. *Anim Reprod* 2007; 4:63-69.  
Hibi H *et al.* Treatment of oligoasthenozoospermia with tranilast, a mast cell blocker, after long-term administration. *Systems Biol Reproductive Med* 2002; 48(6):451-459.

The GU issues, again, revolve around inflammation, but GU inflammation can be hard to recognize. These patients often present with chronic, migratory, waxing/waning, low-back/flank/pelvic pain. They also often present with frequent urinary tract “infections” except that actual proof of infection is rare. The cultures just keep coming back negative.

The disease can clearly impact the kidneys, libido, and fertility.

[Slides 64-67: Case: Are you sure it's cancer?]

## Case: Are you sure it's cancer?

- In 2006 a 72 year old man underwent prostatectomy for T3bNoMo prostate cancer discovered when screening found a PSA of 10.
- PSA returned to zero after prostatectomy but quickly started rising again.
- Hormonal therapy was started. PSA was quickly suppressed back to zero, but therapy was stopped after a year due to intolerable diffuse bone pain.
- PSA started rising again in 2008 and was observed.

## Case: Are you sure it's cancer?

- In 2010 (PSA 6) he presented with progressive pelvic and bilateral flank pain.
- Staging found no macroscopic disease.
- He declined hormonal therapy.
- Chemotherapy quickly returned the PSA to normal, but his pelvic and flank pain did not improve.
- Cystoscopies were unrevealing.
- Imaging showed intermittent hydronephrosis.
- Bilateral nephrostomies only worsened the flank pains.

## Case: Are you sure it's cancer?

- Additional PMH/ROS found multiple problems since at least 1990: chronic fatigue, fibromyalgia, presyncope, urinary hesitancy, headache, chills, sweats, pruritus, proximal dysphagia, insomnia, anxiety, depression, nightmares, absent libido, erectile dysfunction, eye and throat irritation, dyspnea, non-anginal chest pain, constipation, refractory GERD, cognitive dysfunction, sensory neuropathy, hypertension, asthma, and multiple odd medication sensitivities.



## Case: Are you sure it's cancer?

- Serum chromogranin A: 90 ng/ml (normal 0-50)
- Neuron-specific enolase: 17 µg/l (normal 3.7-8.9)
- sPGD<sub>2</sub> 115 pg/ml (normal 35-115)
- Histamine blockade and pentosan immediately resolved his GU tract pain and significantly improved many other chronic symptoms.

In 2006 a 72 year old man underwent prostatectomy for what was called a locally advanced prostate cancer discovered when a screening prostate specific antigen (PSA) was modestly elevated at 10 ng/ml. His prostate was removed and his PSA quickly returned to zero, but then it quickly started rising again, which is a fairly common scenario with localized prostate cancer. Hormonal therapy was started, and the PSA dropped back to zero, but he couldn't tolerate the therapy and stopped it. His PSA started rising again, but initially he was just observed. In 2010 his PSA was still at a very modest 6 ng/ml when he presented with progressive pelvic and bilateral flank pain. There was no detectable evidence of prostate cancer beyond the PSA, but there was no other apparent explanation for his pain. So the team of oncologists treating his prostate cancer decided this PSA elevation must be prostate cancer, and he was started on chemotherapy which did knock the PSA back down to zero, but his pain did not improve – a situation akin to the MCAS-induced polycythemia case. He also had mysterious intermittent hydronephrosis of no identifiable cause. When I first took his history, a bevy of issues ongoing for 20 years emerged. Serum chromogranin A was elevated. PGD<sub>2</sub> was top end of normal. Histamine blockade and pentosan (a mast cell stabilizer helpful with GU tract disease) immediately resolved his pain and significantly improved many other chronic symptoms. I suspect what had been causing the episodic hydronephrosis

Mastocytosis Society Canada Medical Lecture – June 6, 2011

Contact: [info@mastocytosis.ca](mailto:info@mastocytosis.ca) or [afrinl@musc.edu](mailto:afrinl@musc.edu)

Systemic Mast Cell Disease: An Update – L. Afrin, M.D., Medical University of South Carolina

was flaring of ureteral mast cell disease causing ureteral edema to the point of obstruction.

[Slide 68: MCAS: Presentation.]

## MCAS: Presentation

- Musculoskeletal
  - Myositis (often subclinical)
  - Osteopenia/osteoporosis out of proportion to age, diet, etc.
- Joints
  - Diffusely migratory arthralgias
    - Many patients previously diagnosed with fibromyalgia
- Mast cell-derived pain is often poorly responsive to traditional analgesics
  - Many analgesics (e.g., NSAIDs, narcs) exacerbate symptoms

Lucas HJ et al. Fibromyalgia—new concepts of pathogenesis and treatment. Int J Immunopathol Pharmacol 2006;10:5-10.

Unsurprisingly, there's a broad range of musculoskeletal issues in MCAS, too, including osteopenia (thinning of the bones) or osteoporosis out of proportion to age or diet. Also, these patients sometimes will have an elevated creatine kinase and/or elevated aldolase despite having no muscle symptoms at all. Other symptoms include diffusely migratory arthralgias. Many MCAS patients have been diagnosed previously with "fibromyalgia." They often poorly respond to all traditional analgesics (painkillers), which actually can make them worse.

[Slide 69: MCAS: Presentation.]

## MCAS: Presentation

- Neurologic
  - Headache (especially migraine)
  - Dizziness, syncope, “dysautonomia”
  - Demyelinating processes
    - Weakness
    - Tics
    - Distal sensory neuropathy
    - Acute and chronic inflammatory demyelinating neuropathies
    - Multiple sclerosis?
    - ALS?
      - PGD<sub>2</sub> induces motor neuron loss through demyelination and enhanced astrogliosis; motor neuron PGD<sub>2</sub> receptor blockade rescues them.

Mezei Z *et al.* Platelet arachidonate cascade of migraines in the interictal phase. *Platelets* 2000 Jun;11(4):222-5.  
Theoharides TC *et al.* Differential release of mast cell mediators and the pathogenesis of inflammation. *Immunological Reviews* 2007;217(1):65-78.  
Secora VH *et al.* Mast Cells Are Essential for Early Onset and Severe Disease in a Murine Model of Multiple Sclerosis. *J Exper Med* 2000;191(5):823-827.  
Mohri I *et al.* Prostaglandin D<sub>2</sub>-Mediated Microglia/Astrocyte Interaction Enhances Astrogliosis and Demyelination in *Drosophila*. *J Neuroscience* 2006 Apr 19;26(16):4383-4393.  
Marchetto MCN *et al.* Non-Cell-Autonomous Effect of Human SOD1<sup>G93A</sup> Astrocytes on Motor Neurons Derived from Human Embryonic Stem Cells. *Cell Stem Cell* 2008 Dec 4;3(6):640-657.  
Di Giorgio FP *et al.* Human Embryonic Stem Cell-Derived Motor Neurons Are Sensitive to the Toxic Effect of Glial Cells Carrying an ALS-Causing Mutation. *Cell Stem Cell* 2008 Dec 4;3(6):637-648.

Neurologic issues, too, are all over the map, including headaches, especially migraines. I have now lost count of the number of these patients who've come to me over the last few years with refractory migraine headaches, and simple antihistamines were all it took to eliminate the headaches. To be sure, this approach has not worked for all of my MCAS patients with migraine headaches, but it has helped a not insignificant number of them. Again, it just emphasizes the importance of getting the right diagnosis. Syncope and dizziness are common complaints, and many of my patients labeled with POTS have also been labeled with dysautonomia. There can be actual demyelination. Many MCAS patients have migratory sensory neuropathies (tingling and numbness) that migrates around, but it also waxes and wanes, and if you follow it over time it's clear it's not a true demyelination going on. There's growing evidence implicating mast cell disease in multiple sclerosis and amyotrophic lateral sclerosis, but we haven't found the “smoking gun” yet to definitively attribute those diseases to mast cell disease.

[Slide 70: MCAS: Presentation.]

## MCAS: Presentation

- Neurologic
  - Sleep
    - PGD<sub>2</sub> is the most potent human (non-REM) somnogen known
      - Known receptors for PGD<sub>2</sub> in the sleep center in or near the preoptic area
    - Sleeping sickness patients have elevated CSF PGD<sub>2</sub> (likely made by trypanosomes, which are capable of prostaglandin synthesis from arachidonic acid using PG synthases distinct from their mammalian counterparts)
    - Obstructive sleep apnea common
      - Can contribute significantly to fatigue and headache (esp. a.m.)

Urade Y, Hayaishi O. Prostaglandin D<sub>2</sub> and sleep regulation. *Biochim Biophys Acta* 2009 Jan 4;1786(1):606-615.  
Hayaishi O. Molecular mechanisms of sleep-wake regulation: roles of prostaglandin D<sub>2</sub> and E<sub>2</sub>. *FASEB J* 2001 Aug 5;15:1575-1581.  
Scammell TE et al. Activation of ventrolateral preoptic neurons by the somnogen prostaglandin D<sub>2</sub>. *Proc Natl Acad Sci U S A* 2008 Jun 3;105:7754-7759.  
Pearce RW et al. The somnogenic T-lymphocyte suppressor prostaglandin D<sub>2</sub> is selectively elevated in CSF of advanced sleeping sickness patients. *Trans R Soc Trop Med Hyg* 2000;84:705-709.  
Kubota BK et al. Identification of a novel prostaglandin F<sub>2</sub> synthase in *Trypanosoma brucei*. *J Exper Med* 2000;192(10):1327-1338.  
Kilunga BK et al. Structural and mutational analysis of *T. brucei* prostaglandin H<sub>2</sub> reductase provides insight into the catalytic mechanism of aldo-ketoreductases. *JBC* 2005 Jul 15;280(28):26571-26581.

Sleep issues are quite common. It's usually insomnia, but I've now seen virtually every type of sleep disturbance across my pool of MCAS patients. Certain mast cell mediators can cause interesting sleep disturbances. Weight gain can lead to obstructive sleep apnea which can produce a whole range of its own symptoms. Sometimes, if you just treat the sleep apnea, you can get significant symptomatic improvement. Conversely, I've also seen a number of MCAS patients who are very slim but clearly have obstructive sleep apnea. I'm beginning to wonder if there's some mediator imbalance that affects pharyngeal muscle tone during sleep so that even if you're not obese, you might still be able to develop obstructive sleep apnea.



[Slide 71: MCAS Presentation]

## MCAS: Presentation

- Neurologic
  - Other known CNS effects of  $PGD_2$ 
    - Osmoregulation
    - Temperature regulation
    - Neuroendocrine control
    - Pain perception
    - Vasomotor control
  - Developmental?
    - Autism is 5-8 times more frequent in patients with mastocytosis

Scannell T *et al.* Activation of ventrolateral preoptic neurons by the somnogen prostaglandin  $D_2$ . *Proc Natl Acad Sci* 1998 Jun 23;95(13):7754-7759.

Lipton JM, Clark WG. Neurotransmitters in Temperature Control. *Annu Rev Physiol* 1986;48:613-623.

Uda R *et al.* Nociceptive effects induced by intrathecal administration of prostaglandin  $D_2$ ,  $E_2$ , or  $F_{2\alpha}$  to conscious mice. *Brain Res* 1990 Feb 26; 510(1):26-32.

Theoharides TC *et al.* Novel therapeutic targets for autism. *Trends Pharmacol Sci* 2008;29:375-382.

The disease clearly impacts a number of hormonal issues helping you to better understand the constitutional symptoms.

Furthermore, we now know that autism is up to 10 times more frequent in patients with mastocytosis, making me wonder if chronic expression of certain specific aberrant mediator patterns could impact neural development so as to lead to autism. We don't know. Right now this is just a statistical association between autism and mast cell disease, but, given the known biology of the mast cell, it's a biologically plausible theory which also could explain other curious aspects of the autism such as the anecdotal reports of the condition developing relatively soon after acute reactions to routine childhood vaccinations.

[Slide 72: MCAS: Presentation.]

## MCAS: Presentation

- Neurologic
  - Other known CNS effects of  $PGD_2$ 
    - Osmoregulation
    - Temperature regulation
    - Neuroendocrine control
    - Pain perception
    - Vasomotor control
  - Developmental?
    - Autism is 5-8 times more frequent in patients with mastocytosis

Scammell T *et al.* Activation of ventrolateral preoptic neurons by the somnogen prostaglandin  $D_2$ . *Proc Natl Acad Sci* 1998 Jun 23;95(13):7754-7759.

Lipton JM, Clark WG. Neurotransmitters in Temperature Control. *Annu Rev Physiol* 1986;48:613-623.

Uda R *et al.* Nociceptive effects induced by intrathecal administration of prostaglandin  $D_2$ ,  $E_2$ , or  $F_{2\alpha}$  to conscious mice. *Brain Res* 1990 Feb 26; 510(1):26-32.

Theoharides TC *et al.* Novel therapeutic targets for autism. *Trends Pharmacol Sci* 2008;29:375-382.

The psychiatric issues in MCAS are just as broad-ranging as the symptoms found in every other system. There is no major DSM Axis 1 disorder that has not been diagnosed in a patient with mast cell disease. Maybe Axis 2 disorders tie into this as well, but we don't know.

[Slides 73-75: Case: PTSD without the T?]

## Case: PTSD without the T?

- A 72 year old veteran presented for further evaluation and management of mantle cell lymphoma (MCL) refractory to multiple therapies.
- PMH/ROS included long histories of hypertension, diabetes, cardiac and peripheral atherosclerosis, chronic fatigue, fibromyalgia, and GERD.
- Depression, anxiety, and nightmares of his Korean War service had led to diagnosis of PTSD in his 30s, but it had never responded well to psychotherapy or psychotropic medications.

## Case: PTSD without the T?

- On further evaluation:
  - His lymphoma did not bear classic MCL molecular markers and histologically was not classic for MCL but was reported as “most consistent” with MCL.
  - He had never experienced battle. Before deployment to the front, he experienced two episodes of spontaneous, unprovoked syncope the first two days after arriving in Seoul (each time while walking down the street with others from his unit) and was discharged.

## Case: PTSD without the T?

- Chromogranin A and sPGD<sub>2</sub> moderately elevated.
- Histamine blockade yielded prompt partial relief of multiple symptoms.
- A novel chemotherapy regimen is being tried.

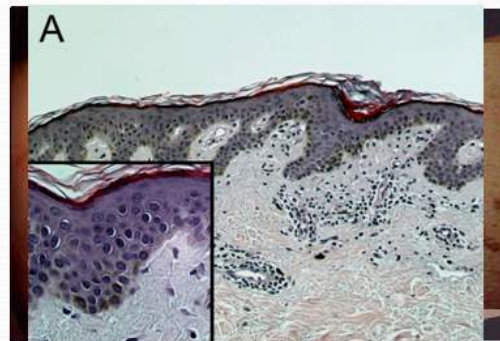
A 72 year old veteran presented for further evaluation and management of mantle cell lymphoma refractory to multiple therapies. We took a detailed history and found a lot of problems that had been going on for decades which could not possibly be attributed to his lymphoma. Most interestingly, he also had PTSD (post traumatic stress disorder) from his Korean War service. He'd had this diagnosis since his 30's, but he had never responded to any therapy for it. On first evaluation for lymphoma, it didn't look like the classic picture of lymphoma, and when we went into the history of PTSD, I asked him to tell me about his war experience. He said he didn't have any. He went through basic training, was deployed to Korea, landed in Seoul and had 2 days before being shipped to the front. He was walking down the street and passed out on two different occasions. The Army discharged him because of that. Ten years later the battle nightmares began. He was diagnosed with PTSD (again underscoring the importance of an accurate history), but it was never successfully treated and his symptoms persisted despite multiple medication trials and efforts at various types of talk therapy. He turned out to have an elevated serum chromogranin A. He does have lymphoma, but closer examination of the pathology found it actually wasn't mantle cell lymphoma and now the pathologist has decided he can only call it a non-classifiable lymphoma.



[Slide 76: MCAS: Presentation.]

## MCAS: Presentation

- Dermatologic
  - Rash with persistent and/or migratory components
    - Red-brown macular, maculopapular “freckle” lesions and/or telangiectasias
    - Erythema ranging from small patches to diffuse skin involvement
    - In less-than-aggressive forms of disease, mastocytes almost always clustered around vessels
  - Pruritus
  - Pain
  - Flushing
  - Angioedema
  - Dermatographism



Dermatologic issues, too, are “all over the map.” Fundamentally, this disease seems as if it can make your skin do anything. Dermatographism is quite frequent, and pruritis can be very troublesome.

[Slide 77: MCAS: Presentation.]

## MCAS: Presentation

- Hematologic
  - Often a 100% normal CBC and leukocyte differential! Or any or all of...
  - ...polycythemia (typically mild and JAK2-negative) or anemia
    - Polycythemia often a result of “paraneoplastic” release of erythropoietic mediators (e.g., epo)
    - Anemia may be:
      - Normocytic (“anemia of chronic inflammation”)
      - “Idiopathically” macrocytic (from reticulocytosis driven by erythropoietic mediators and/or from aberrant erythrocytic maturation (e.g., “myelodysplasia”))
      - Microcytic (from disease-induced Fe or Cu malabsorption or use of acid suppressants for disease-induced “refractory GERD”, though occasionally just a coincidental hemoglobinopathy)
  - ...leukocytosis or leukopenia
    - Chronic subtle relative monocytosis is common
    - Often with subtle/intermittent relative eosinophilia and/or basophilia, too
  - ...thrombocytosis (JAK2 + or -) or thrombocytopenia
  - ...“idiopathic” clotting and/or bleeding/bruising
    - Often with chronic subtle abnormalities of PT and/or PTT (antiphospholipid antibodies?)
    - Elevated circulating heparin in ~90% of MCAD patients regardless of PTT status\*
  - Marrow:
    - Usually does not show increased or aberrant mast cells
    - Often interpreted as non-specific/undefined myelodysplastic/myeloproliferative syndrome

Afrin LB. Mast Cell Activation Disorder Masquerading as Pure Red Cell Aplasia. *Int J Hematol* 2010;91:907-908.

Afrin LB. Mast Cell Activation Disorder Masquerading as Agranulocytosis. *MilMed*, submitted.

\*Molderings GJ. Personal communication, May 31, 2011.

The most common hematologic presentation of this hematologic disease is a 100% normal CBC, which in my experience seems to confound most hematologists given that mast cell disease is classified as a hematologic disease. It certainly confounded me, too, at least initially. However, it's clear that mast cell disease can present with any or all of the hematologic problems listed on this slide including polycythemia or anemia (i.e., too many or too few red cells, which can be normal, enlarged, or reduced in size for various reasons), too many or too few white cells, too many or too few platelets, and/or too much or too little clotting. The most common abnormal presentation in peripheral blood in these patients is a chronic subtle relative monocytosis (not an absolute monocytosis). If you look at the white cell differential, where the upper limit of normal for monocytes is about 10%, you'll see modest elevations – a few percentage points at most – above that limit. If you look at that long list of mediators these cells elaborate, monocyte growth factor is on the list. I don't know that that's the growth factor that's causing the increase in monocytes, but clearly there are growth factors being elaborated by the disease that are capable of increasing monocytes.

Now with regard to your difficulty getting the PGD<sub>2</sub> testing, again, I got information just last week that you can find elevated circulating heparin in about 90% of these patients. So I don't know if the plasma heparin level is any easier for you to get than the PGD<sub>2</sub>, but if so, that may be the test to go for. The upper limit of normal varies amongst laboratories but typically is 0.020 anti-Factor-Xa units/ml. Many of these patients will have elevated levels of heparin even if the partial thromboplastin time (PTT) is normal. In MCAS, the most common marrow pattern is completely normal findings on every test including histology, flow cytometry, cytogenetics, and mutation analysis by polymerase chain reaction. The most common abnormal pattern is a non-specific myelodysplastic/myeloproliferative syndrome, which is the pathologist's way of telling you something isn't quite right about the marrow, but they can't figure out what the problem specifically is. Often, once the pathology report has mentioned that term of myelodysplasia, the patient gets diagnosed with "cytogenetically normal myelodysplastic syndrome," the hematologist never thinks about mast cell disease, and the patient winds up getting treated for myelodysplastic syndrome with no good results because that's the wrong diagnosis and the wrong treatment.

[Slides 78-79: Case: Too Many or Too Few Red Cells]

## Case: Too Many Red Cells

- What portion of the 2% of cases of JAK2-negative polycythemia vera are MCAS?
- What portion of the cases of JAK2-negative, otherwise idiopathic polycythemia are MCAS?

## Case: Too Few Red Cells

- What portions of the following anemic syndromes might be MCAS?
  - Otherwise idiopathic aplastic anemia
  - Parvovirus B19-negative acquired pure red cell aplasia
  - Congenital anemias (e.g., Diamond-Blackfan)
  - Anemia of chronic disease/inflammation
  - Myelodysplastic syndrome without detectable genetic anomalies
  - “Bad-phenotype” sickle cell anemia
- If you don’t look...

A number of polycythemias or anemias which presently are idiopathic but which seem to well fit MCAS (e.g., anemia of chronic disease/inflammation, poorly behaving sickle cell anemia) might in fact be MCAS, or at least MCAS as an acquired co-morbidity to the inborn disease.



[Slides 80-82: Case: Too Few White Cells]

## Case: Too Few White Cells

- At age 57 a morbidly obese, hypertensive, diabetic man was diagnosed with CCP-positive rheumatoid arthritis.
- PMH included depression, anxiety, fatigue, chronic atrial fibrillation, impotence, gynecomastia, mild dyspnea, GERD, obstructive sleep apnea, idiopathic diarrhea, presyncope, rash, edema, and poor tolerance of flu vaccines.
- Arthritis was refractory to NSAIDs, methotrexate, and hydroxychloroquine; steroids helped, but symptoms relapsed on taper. At age 58, sulfasalazine was begun.

## Case: Too Few White Cells

- One month later sulfasalazine was stopped due to non-response. The plummeting of the previously normal absolute neutrophil count to zero was missed.
- Repeated “URIs” ensued, initially mild (permitting outpatient treatment) but worsening over time. No infectant was ever identified. ANC remained zero and remained overlooked.
- At age 61 he was referred for evaluation of newly recognized agranulocytosis.

## Case: Too Few White Cells

- Extensive evaluation (incl. marrow) was negative.
- He was refractory to trials of PEG-G-CSF and abatacept.
- At age 64, tryptase 15 ng/ml (normal 2-10) and 24-hour uPGD<sub>2</sub> 1,078 ng/24h (normal 100-280) were found.
- Histamine blockade, leukotriene antagonism, and oral cromolyn were unhelpful.
- At age 65, imatinib 100 mg/d immediately increased neutrophils to 25%.
- Histamine blockade was restarted and aspirin added.
- Symptoms and neutropenia immediately resolved; improvement has been sustained 18 months.

I've shown you a case with too many red cells, and I've shown you a case with too few red cells. Here now is a white cell issue. At age 57 a morbidly obese hypertensive diabetic was diagnosed with rheumatoid arthritis. He had many problems, but the rheumatologist could focus only on the arthritis, which proved to be refractory to multiple drugs. Steroids helped only a little bit. Finally, he was given sulfasalazine, which was stopped one month later because it wasn't helping his arthritis. His primary care physician failed to notice at that time, in spite of having ordered a CBC, that the absolute neutrophil count (ANC) had dropped to zero. Now, agranulocytosis is a recognized potential complication of sulfasalazine, but when you stop the drug, the ANC is supposed to rebound. That did not happen here. Repeated upper respiratory "infections" ensued even though no infectant could ever be found. At age 61, three years later, finally the ANC of zero was seen despite there having been many interim CBCs in which the agranulocytosis was never recognized. He was referred to me and underwent an extensive evaluation, including a marrow exam, all of which was unrevealing. Finally, we had an opportunity to check for mast cell disease. Tryptase was only modestly elevated and did not meet WHO criteria. However, he had the third highest level of PGD<sub>2</sub> I've ever seen. I tried inexpensive interventions, but none of them worked. I then tried him on low dose imatinib, and immediately the ANC rebounded from 0 (where it had been for

6 years at that point). He was beginning to have serious infections and unhealed wounds and lots of surgery to heal them, but imatinib got the ANC up to 25%, and then I decided to try adding aspirin along with some protective antihistamines. I had not done aspirin initially because he was also on warfarin, but then we decided to at least briefly try it. He tolerated it well with no apparent complications, and his ANC immediately reverted to normal with just a modest 325 mg aspirin dose added to imatinib.

**Shelley:** Earlier you mentioned that when you are KIT-positive that imatinib sometimes can help. Are these cases KIT-positive?

**Dr. Afrin:** We don't know in him because we couldn't do the GI biopsies safely due to his being on warfarin. I suspect the reason imatinib can work in some patients with the D816V mutation is that most of these patients have multiple mutations. We know imatinib can stabilize some of the other mutations, i.e., it doesn't focus just on the D816V mutation. We don't exactly know the molecular mechanism yet of how it stabilizes the other mutations or which ones. The fundamental issue with mutations is that although KIT is ordinarily quiescent until it gets activated by stem cell factor, these mutations lead to constitutive activation of KIT. Once KIT is always on, you've got to find a way to stabilize it.

[Slides 84-86: Case: Too few platelets.]

## Case: Too Few Platelets

- A 4 year old girl developed frequent bilateral otitis media and multiple severe allergies.
- Iriditis set in at age 10.
- By age 18 chronic dysmenorrhea, fibroids, endometriosis, and migraines began.
- In her 20s chronic fatigue, fibromyalgia, frequent infections at many sites, poor healing and post-op bleeding, and irritable bowel syndrome set in.
- In her 40s hypertension, severe GERD, urinary incontinence, Sjogren's syndrome, Hashimoto's thyroiditis, dyspnea NOS, and MGUS were diagnosed.



## Case: Too Few Platelets

- Referred at age 50 for thrombocytopenia; work-up consistent with ITP.
- ROS positive for fevers, chills, sweats, headaches, sinusitis, pruritus, mouth and throat soreness, CPAP-refractory obstructive sleep apnea (non-obese!), palpitations, malaise, sensory neuropathies, edema, insomnia, depression, dyspareunia, cognitive dysfunction, frequent presyncope.
  - Was this really Sjogren's?
- Tryptase elevated 2.5-fold; duodenal mast cells ↑'ed

## Case: Too Few Platelets

- No response to histamine blockade or NSAIDs, intolerant of oral cromolyn and montelukast.
- After one week of imatinib 200 mg/d, all symptoms resolved and platelet count normalized.
- Response sustained six months so far.

I'm skipping over cases because we're running late.

This basically was a case of ITP. She had had multiple problems throughout her life going back to childhood and was eventually referred for consideration of immune thrombocytopenic purpura (low platelets) evolving due to Sjogren's Syndrome. Her Sjogren's Syndrome was not really behaving like Sjogren's Syndrome is supposed to behave, but we also found her tryptase was elevated, mast cells were increased in the duodenum, and eventually she turned out to do well – symptoms and platelet count – on imatinib.

[Slides 87-88: Case: Too Much Clotting.]

## Case: Too Much Clotting

- A 51 year old morbidly obese diabetic woman was referred for further evaluation of hypercoagulability including two strokes, multiple pulmonary emboli, and extensive superficial venous thromboses.
- Extensive hypercoagulable work-up found only heterozygous MTHFR A1298C and PAI-1 4G/5G.
- Clots refractory to warfarin, enoxaparin, fondaparinux
- PMH/ROS found virtually lifelong chronic fatigue, fibromyalgia, frequent respiratory/urinary infections without hypogammaglobulinemia, idiopathic dyspnea/cough occasionally requiring home O<sub>2</sub>.

## Case: Too Much Clotting

- Tryptase, histamine, chromogranin A, aldolase and uPGD<sub>2</sub> all found mildly elevated.
- Marrow normal, but flow cytometry found tiny (< 0.1%) populations of CD117/CD25 and CD117/CD2 mast cells.
- Histamine blockade brought prompt partial relief, but extensive subcutaneous thromboses persisted.
- After one week of imatinib 200 mg/d, all subcutaneous thromboses had vanished.
- Response has been sustained 10 months thus far.

A 51 year old morbidly obese diabetic woman was referred for further evaluation of hypercoagulability including lots of clots. Her exam was really impressive. You could feel multiple superficial venous clots all over her skin. Extensive workup found just a couple of modest abnormalities that couldn't possibly account for such severe clotting. She was refractory to multiple agents. She turned out to have multiple positive markers for MCAS, and she was one of the few MCAS patients who actually showed an abnormal population of mast cells in her marrow, though, as usual in those few MCAS patients who have positive marrow findings, this was detectable only on flow cytometry. Histamine blockade brought prompt partial relief of some symptoms, but the thromboses persisted. Then I put her on low-dose imatinib, and she came back a month later with complete resolution of all of the superficial thrombosis. Due to financial issues, she stopped imatinib, and all of her prior problems came back. She then was able to resume imatinib, and all of her problems went away again.

[Slides 89-90: Case: Too Little Clotting.]

## Case: Too Little Clotting

- A 22 year old referred herself after realizing she might have the MCAS her 17 year old brother had just had diagnosed as the root of his 7 year ordeal of idiopathic presyncope and severe abdominal pain.
- Her many idiopathic problems dated to early childhood and included frequent epistaxis, frequent “UTIs” (infectants rarely found), idiopathic bilateral knee pain requiring synovectomies at age 17, chills, headaches, exercise-induced pruritus, chronic eye/nose/throat irritation, asthma, palpitations, GERD, IBS, presyncope, and syncope.



## Case: Too Little Clotting

- Investigation found elevated plasma histamine and heparin.
- Patient had previously proved refractory to pentosan prescribed by her gynecologist who thought her GU tract issues were interstitial cystitis.
- Histamine blockade brought prompt partial relief of many symptoms.
- Additional treatments are being explored.

A 22 year old woman referred herself after realizing she might have MCAS since her 17 year old brother had just been diagnosed with MCAS as the root of his seven year ordeal. Her many problems included frequent epistaxis which had undergone extensive evaluation, and her physicians (including ENT physicians) could never find a cause for it. She also had many other problems. She was found to have an elevated plasma histamine and elevated heparin, and her intractable pelvic pain turned out to be an interstitial cystitis. She has responded somewhat to histamine blockade.

[Slides 91-95: MCAS: Presentation.]

## MCAS: Presentation

- Immunologic
  - Hypersensitivities
    - Involved in Type I, II, III, and IV hypersensitivity reactions
  - Malignancy
    - Due to impaired immune surveillance?
    - Often diagnosed and treated without recognition of the underlying problem
    - More commonly hematologic, most commonly myeloid

Sayed BA *et al.* The Master Switch: The Role of Mast Cells in Autoimmunity and Tolerance. *Annu Rev Immunol* 2008 Apr;26:705-739.

Trivedi SG *et al.* Essential role for hematopoietic prostaglandin D<sub>2</sub> synthase in the control of delayed type hypersensitivity. *Proc Natl Acad Sci* 2006 Mar 28; 103(13):5170-5184.

Galinsky DS, Nechushtan H. Mast cells and cancer – no longer just basic science. *Crit Rev Oncol Hematol* 2008 Nov;68(2):115-30.

## MCAS: Presentation

- Immunologic
  - Autoimmunity (often subclinical, even with high autoantibody titers)
  - Evidence for mast cell etiologic involvement exists in many autoimmune diseases including:
    - Autoimmune hypo- and hyper-thyroidism
    - Bullous pemphigoid
    - Pemphigus vulgaris
    - Rheumatoid arthritis
    - SLE
    - Insulin-dependent diabetes mellitus
    - Multiple sclerosis
    - Guillain-Barré syndrome
    - Sjogren's syndrome
    - Systemic sclerosis
    - Autoimmune vasculitides
    - Autoimmune enteropathies (UC, Crohn's)

Until methods for demonstrating MC monoclonality are readily available, distinction of MCAS from autoinflammatory syndromes will continue to require high indices of suspicion and expensive genetic testing.

Sayed BA et al. The Master Switch: The Role of Mast Cells in Autoimmunity and Tolerance. *Annu Rev Immunol* 2008 Apr;26:705-739.

# MCAS: Presentation

- Immunologic
  - Autoimmunity
    - Mast cells influence initiation and effector phases of autoimmune diseases via many mechanisms including:
      - Promoting dendritic cell maturation and migration to secondary lymphoid organs
      - Directing T cell differentiation
      - Orchestrating the migration of T cells and other immune cells to the sites of tissue inflammation
    - Variable effects of mast cells are related to:
      - The activating stimulus
      - Tissue site
      - Proximal target cells
      - Genetically determined variability in mediator production

## MCAS: Presentation

- Infectious
  - Mast cells express TLR1, TLR2, TLR3, TLR4, TLR7, and TLR9
    - Important in response to bacteria, viruses, parasites
  - In addition to proinflammatory effects, mast cells have suppressive effects on some immune responses
  - Patients often have increased troubles with infection
    - More frequent infection than they previously experienced
      - Common and uncommon sites
      - Common and uncommon organisms
    - More prolonged infectious episodes even in spite of known correct antibiotic therapy



## MCAS: Presentation

- Impaired healing
  - The activated mast cell controls the key events in wound healing:
    - Triggering and modulation of the inflammatory stage
    - Proliferation of connective cellular elements
    - Final remodelling of newly formed connective tissue matrix
  - Surplus or deficit or degranulated mediators impairs repair:
    - Exuberant granulation tissue
    - Delayed closure
    - Chronic inflammation

Trabucchi E et al. The role of mast cells in wound healing. *Int J Tissue Reactions* 1088;10(6):367-372.

Immunologic issues are all over the map, too.

With mast cell diseases, the risks of malignancy seem to be increased, likely due to impaired immune surveillance which comes about because of the impact of the mediator expression pattern on immune system function. The malignancies are more commonly hematologic, most commonly myeloid, and can be solid tumour. You also get auto-immunity problems across the board in MCAS patients, plus increased troubles with infections, both the common and uncommon sites and organisms, and they just take longer to resolve even with known correct antibiotics. MCAS patients also just don't heal normally, both from infections and from wounds. Mast cells are known to be critical to proper wound healing.

[Slide 96: MCAS: Presentation.]

## MCAS: Presentation

- Endocrinologic/metabolic
  - Delayed puberty/menarche, irregular menses, endometriosis
  - Osteosclerosis, osteoporosis
  - Hypo/hyperthyroidism
    - Hypo more commonly than hyper
    - Usually autoimmune
  - Hyperferritinemia (likely inflammatory)
  - Electrolyte abnormalities (high or low)
  - Lipid abnormalities (often hypercholesterolemia)

Kempuraj D et al. Increased numbers of activated mast cells in endometriosis lesions positive for corticotropin-releasing hormone and urocortin. *Am J Reprod Immunol* 2004;52:267-275.

Chiappetta N, Gruber B. The Role of Mast Cells in Osteoporosis. *Semin Arthritis Rheumatism* 2006 Aug;36(1):32-36.

Alfter K et al. New aspects of liver abnormalities as part of the systemic mast cell activation syndrome. *Liver International* 2010;29(2):181-186.

The endocrinologic issues are wide-ranging, too, and include delayed puberty, delayed menarche, endometriosis, irregular menses, bone problems (too much bone and/or too little bone), and too much or too little thyroid function. Hyperferritinemia can be present to an astounding degree, and it's likely inflammatory. (Ferritin itself is a known mast cell mediator product, too.) Electrolyte abnormalities and lipid abnormalities are often present, and sometimes pretty significant hypertriglyceridemia can be seen such as in this (next) patient.

**Dr. Sibbald:** Of the people here, are there any of these abnormalities that would clue you in to anything specifically? (All indicated No.)

[Slides 97-98: Case: Endocrinologic Chaos.]

## Case: Endocrinologic Chaos

- A boy began suffering frequent fractures (about all bones and teeth) at age 2. Extensive evaluation over many years found no genetic or acquired cause for his severe osteopenia.
- Other childhood problems included frequent migraines, alternating diarrhea and constipation.
- In late adolescence, irritated eyes, frequent “viral syndromes,” and episodic depression/anxiety began.
- In his 30s: fatigue, fibromyalgia, arthritis, rash, subtle dyspnea, presyncope, flushing, and palpitations.

## Case: Endocrinologic Chaos

- At age 39 a consulting endocrinologist found a minimally elevated tryptase; subsequent evaluation found a minimally elevated 24-hour urinary PGD<sub>2</sub> and minimally increased duodenal and colonic mast cells
- Immediate partial response to histamine blockade
- Intolerant of aspirin
- At 200 mg/d, imatinib completely resolved longstanding diarrhea and normalized longstanding severe, treatment-refractory hypertriglyceridemia.
- Response sustained since October 2010

**Dr. Afrin:** A boy began suffering frequent fractures at age two. No genetic or acquired cause could be found for the severe osteopenia. Multiple other problems occurred throughout childhood and just got worse and worse as the decades went on. Finally an endocrinologist checked a serum tryptase and found it to be minimally elevated. I then found a minimally elevated urinary PGD<sub>2</sub> and slightly increased GI tract mast cells. He had immediate partial response to histamine blockade. He was intolerant of aspirin. He went on to a trial of low-dose imatinib, which very interestingly not only completely resolved his longstanding diarrhea but also completely resolved his longstanding severe hypertriglyceridemia (about 1800 and utterly treatment refractory) virtually overnight.

**David Girvin:** Do you know what happened to his heparin? Did you measure the heparin after the treatment?

**Dr. Afrin:** I did not.

**David Girvin:** Have you had any (idea) exactly whether his heparin has gone down after treatment?

**Dr. Afrin:** No, and in fact in most of these patients I have not found utility in following the diagnostic marker levels.

**David Girvin:** I'm just curious whether there's a correlation between marker levels and symptoms or findings in other labs.

**Dr. Afrin:** Currently that doesn't appear to be the case.



[Slides 99-101: Case: Why Are Bad Sicklers Bad?]

## Case: Why are Bad Sicklers Bad?

- A girl with sickle cell anemia suffered strokes at ages 3 and 8 resulting in hemiparesis and dysarthria. She was chronically transfused since age 3 and soon developed a serum ferritin of 5-10K; “transfusional hemosiderosis” was refractory to aggressive chelation.
- Other problems over the years included very frequent pain crises with hospitalizations complicated by pneumonia and sinusitis; catheter-associated clots; migraines; fatigue/malaise; constantly bed-bound
- Hydroxyurea since age 20 with little benefit

## Case: Why are Bad Sicklers Bad?

- Chronic lab abnormalities included modest thrombocytosis, monocytosis, eosinophilia, basophilia, elevated PT/PTT; periodic severe anemia; ANA 1:640
- Imaging showed chronic modest retrocrural adenopathy and a normal-sized spleen
- At age 32 she developed severe whole back pain refractory to multiple pain medications
- Serum CGA 89 ng/ml (normal 0-50), plasma tryptase, histamine and uPGD<sub>2</sub>/NMH all top normal

## Case: Why are Bad Sicklers Bad?

- No response to loratadine and famotidine
- Aspirin added, rapidly escalated to 975 mg bid (~\$1/year)
- One month follow-up:
  - All pain gone
  - Out of bed, helping with chores, going out with friends
  - Ferritin normal
- 18 month follow-up:
  - Two crises requiring ER visits/hospitalization; ferritin bumped to ~600 each time, quickly returning to normal
  - Chelation (~\$60K/year) discontinued

**Dr. Afrin:** The vast majority of sickle cell anemia patients are “good sicklers” with only an occasional sickle cell pain crisis; they rarely get hospitalized and are able to be productive members of society. The hematologist’s bane, however, is the “bad sickler.” Bad sicklers are the sickle cell anemia patients who seem to incur many of the known complications of sickle cell disease beyond just the painful vaso-occlusive crises. The question, though, is this: if all sickle cell anemia patients have exactly the same beta-globin mutation, then why do they segregate into good sicklers and bad sicklers? Logically, there must be something beyond the beta-globin mutation causing the bad sicklers to go bad.

A girl with sickle cell anemia suffered strokes at ages 3 and 8 –right away defining her as a bad sickler – resulting in chronic transfusion therapy since age 3 (which obviously did nothing to prevent the stroke at age 8) and soon developed a serum ferritin that was wildly varying between 5,000 ng/ml and 10,000 ng/ml from one determination to the next, with no correlation at all to her transfusion history. The hyperferritinemia, long attributed to her transfusion therapy, was utterly refractory to aggressive chelation with both Desferal and Exjade. Other problems, too, developed over the years, including pneumonias. Interestingly, her pneumonias were never really classic pneumonias. They

were always radiographically diagnosed as a patchy inflammation in one lobe or another, basically just inflammation in the lungs. It was clinically interpreted as pneumonia. She was constantly bed-bound and just couldn't do anything. She was severely malaised. Hydroxyurea didn't help. She had multiple chronic lab abnormalities not attributable to sickle cell disease. I started to get the gist that there was something else going on, because sickle cell anemia couldn't explain many of her problems. For example, how could a 32-year-old sickler have a normal sized spleen? In sickle cell anemia, the spleen has auto-infarcted and shriveled virtually to the vanishing point by the time you're a few years old. And yet multiple physicians, multiple radiologists, never picked up on how severely abnormal her normal-sized spleen was. So finally she got severe whole back pain, refractory to multiple pain medications, and she came to me. I thought the pattern here was such that it couldn't be sickle pain, i.e., there's no question you have sickle cell anemia, but sickle cell anemia doesn't behave like this, so you must have something else, and what might that be? I began looking for MCAS and quickly found multiple elevated mediators. She did not respond to antihistamines, but then I added aspirin. You start low because of the risks of NSAIDs triggering the disease to flare, but then quite often you're able to ramp the NSAID dose up pretty high. Dr. Jack Roberts at Vanderbilt, in some of his patients, goes as high as 1300 mg four times daily, targeting a plasma salicylate level of 20-30 mg/dl. I don't go that high. From what I've observed, if you're not getting better by around 1300 mg 2-3 times daily, then aspirin is not going to be of significant help. Regardless of the dose, aspirin is extremely cheap. She achieved excellent control and seemed to transform overnight from a "bad sickler" to a "good sickler," bounding out of bed, going on shopping and fishing trips, helping with family chores, basically just being a very happy person, and by the very next determination her ferritin of 5,000 ng/ml had fully normalized (under 300 ng/ml) and has remained normal ever since except for two pain crises (sickle cell? MCAS? both?) for which she was hospitalized. In each of these two crises the ferritin bumped up to around 600 and then as soon as the crisis settled down, the ferritin went back to normal. Her chelation treatment, which she had received for many years and which was costing \$60,000 a year, was discontinued.



[Slide 102: MCAS: Presentation.]

## MCAS: Presentation

- Endocrinologic/metabolic
  - Obesity?
    - Adipose tissue is a reservoir of mast cell precursors which differentiate to mast cells which migrate to mucosal linings and skin
    - $\text{PGD}_2$  metabolite  $15\text{-d-PGJ}_2$  binds to  $\text{PPAR}_\gamma$  (dominantly expressed in adipose tissue, adrenals, and spleen), stimulating transcription of target genes controlling adipocyte differentiation and glucose homeostasis
    - Known association of obesity with chronic low-grade inflammation with elevated circulating leukocytes and cytokines in children and adults
    - Obesity clearly associated with asthma as well as with the incidence and severity of exercise-induced bronchoconstriction
  - Diabetes?

Poglio S *et al.* Adipose tissue as a dedicated reservoir of functional mast cell progenitors. *Stem Cells* 2010. in press; doi:stem.523.  
Ricorte M *et al.* The peroxisome proliferator-activated receptor- $\gamma$  is a negative regulator of macrophage activation. *Nature* 2003 Jan 16; 421(6952):70-82.  
Cooper DM *et al.* Dangerous exercise: lessons learned from dysregulated inflammatory responses to physical activity. *J Appl Physiol* 2007; 103:700-709.  
Beutner DA, Surberland ER. Overweight, obesity and incident asthma: a meta-analysis of prospective epidemiologic studies. *Am J Respir Crit Care Med* 2007; 175:661-666.  
Del Rio-Navarro B *et al.* Exercise-induced bronchospasm in asthmatic and non-asthmatic obese children. *Allergy Immunopathol* 2000; 13:5-11.  
Kaplan TA, Moutana E. Exercise-induced bronchospasm in nonasthmatic obese children. *Clin Pediatr* 2003; 42:220-225.  
Vissel M *et al.* Elevated C-reactive protein levels in overweight and obese adults. *JAMA* 2000; 283:2331-2335.  
Zakharov F *et al.* Body fat and circulating leukocytes in children. *Int J Obes* 2006; 30:906-911.  
Liu J *et al.* Genetic deficiency and pharmacological stabilization of mast cells reduce diet-induced obesity and diabetes in mice. *Nature Med* 2009; 15:940-945.

One has to wonder whether there is a connection between the epidemic of obesity and mast cell disease. I don't have nearly enough time to go into all of the biology here, but there are some very interesting potential links. Adipose tissue is a known reservoir of mast cell precursors.  $\text{PGD}_2$  is intimately involved in at least two key lipid management pathways. There is a known association of obesity with low grade inflammation, though we don't yet know where the inflammation is coming from. There is now a mouse model in which a particular flavour of mast cell disease clearly leads to a classic type 2 diabetic phenotype. So there are potential links between MCAS and diabetes as well.



[Slide 103: MCAS: Approach to Diagnosis]

## MCAS: Approach to Diagnosis

- Physician must appreciate that mast cells in different parts of the body are different
  - Different numbers/density
  - Different morphology
  - Different histochemical properties
  - Different granule size
  - Different granule structure
  - Different granule contents
  - Different sensitivities
  - Different susceptibility to inhibitors

Physicians have to appreciate that mast cells in different parts of the body are different in numbers, density, morphology, granule size, granule content, sensitivities, and different susceptibility to different inhibitors, so to diagnose it...

[Slide 104: MCAS: Diagnostic Criteria.]

## MCAS: Diagnostic Criteria

- Symptoms suggestive of mast cell mediator release
- Objective evidence of mast cell mediator release
  - Tryptase often nl.; pl. histamine/u. N-methylhistamine? pl./u. PGD<sub>2</sub>, PGF<sub>2α</sub>? s. CGA? CPA? F. VIII? pl./u. catechols? pl. heparin? s. TNF? IL-6? VEGF? Serotonin? Prolactin? Gastrin?
    - Continuous chilling critical for many mediators (PGs, histamines, heparin, etc.)
    - NSAID abstinence for prostaglandin samples
    - Stat runs for heparin samples
- ± Abnormal mast cell quantities or phenotypes or genotypes
  - Marrow? GI? Skin? Nodes? Elsewhere?
  - Beware pleomorphic appearance as lymphocytes, plasma cells, histiocytes, macrophages, plasma cells
  - CD117 co-expressed with CD25 and/or CD2
  - D816V and a handful of other KIT mutations seen in SM are the only commercially testable mutations for now
  - Mutations also found in TET2, PDGFRα, RASGRP4, Src kinases, JAK2, etc.
- Failure to meet formal criteria for mastocytosis
- No other evident diagnosis to better explain full range of findings
- Some response to mast-cell-targeted therapy

Akin C et al. Mast cell activation syndrome: proposed diagnostic criteria. *J Allergy Clin Immunol* 2010;126:1099-1104.e4.

...you must have symptoms of mast cell mediator release and you have to find objective evidence of mast cell mediator release. There is no standard approach to doing this. I can't give you a literature-based recommendation on how to do this. I can tell you what my practice is, but it would take more time than we have available right now, so I'll save that for later offline if you're interested. I do check for some of these mediators in initial screens, and if it all comes back negative, then I have a few others I check. There are tricks to running these. Some are technically challenging and/or expensive to run. For PGD<sub>2</sub>, histamine, and heparin, you have to have continuous chilling including, ideally, pre-chilling the specimen container, keeping the container chilled throughout collection, and transporting the specimen on ice to the lab. Some labs are not capable of running some tests and have to send the specimen out to another lab, so care in packing is required to ensure the specimen stays cold for the duration of the long trip.

**Dr. Sibbald:** That ain't gonna happen...

**Dr. Afrin:** But it can happen....

**Dr. Sibbald:** Yeah, but it isn't going to happen here.

**Dr. Afrin:** But it does happen if you take enough time... it's difficult...you have to avoid NSAIDs if you're going to go looking for prostaglandins, and if you're going to do heparin sampling, you must run it stat, so if the lab that's drawing the blood sample for the plasma heparin level can't run the level on-site, then it's not worth drawing the sample, let alone still trying to run the test at a remote reference lab. This need for stat processing ties into why many of these patients have a normal PTT despite an abnormal heparin level.

You can, too, if you want, go hunting for the abnormal cells themselves. I do this if either the patient himself has doubts about the diagnosis or more commonly when both the patient and I know that he's going to run into trouble with other physicians not believing he has a diagnosis based solely on symptoms and mediator levels because many physicians are not trained to understand what an abnormal urinary PGD<sub>2</sub> means, but if you show a physician a pathology report that shows abnormal mast cells, then he may believe it. There has to be failure to meet full criteria for mastocytosis, there has to be no other evident diagnosis that better explains the full range of findings and there has to be some response to mast cell targeted therapy. So, on to the second most important slide in this presentation....

[Slide 105: MCAS: Diagnosis.]

## The 2<sup>nd</sup> Most Important Slide In This Presentation

# MCAS: Diagnosis

- Traditional diagnostic paradigm (symptom A + exam finding B + test result C  $\Rightarrow$  suspect diagnosis D) doesn't work for MCAS
- Instead, need to recognize either of two “metapatterns”:
  - Multiple chronic ailments often unsatisfactorily responsive to  $R_x$
  - Definitively diagnosed ailment which doesn't explain all of the symptoms, findings, and results
- Questionnaires? EMRs?

3	
was marginally elevated.	<input type="checkbox"/> 1
or	
was elevated up to tenfold of the reference value	<input type="checkbox"/> 5
or	
was elevated by more than tenfold of the reference value	<input type="checkbox"/> 10
<i>Imaging methods</i>	
The patient has a splenomegaly and/or hepatomegaly.	<input type="checkbox"/> 1
The patient has bone pain with signs of osteoporosis and/or osteopenia.	<input type="checkbox"/> 1
<i>Medical history</i>	
The patient shows involvement of the skin in terms of brown-redish maculopapular efflorescences, pruritus (itching) without efflorescences and/or disease- related folliculitis	<input type="checkbox"/> 2
a clear increase in the number of telangiectasia	<input type="checkbox"/> 1
The patient reports about sudden attacks of migraine-like headache.	<input type="checkbox"/> 1
The patient reports about memory loss (ability to remember names or words) and/or concentration difficulty.	<input type="checkbox"/> 1
The patient reports about tinnitus attacks and/or ocular discomfort (dry eyes, red eyes, stinging eyes) and/or rhinorrhoea and/or stomatitis (score, if two symptoms are present).	<input type="checkbox"/> 1
The patient reports about sudden attacks of respiratory handicaps (cough, dyspnoea, asthma-like difficulties)	<input type="checkbox"/> 1
In the past, common viral infections of the upper respiratory tract were complicated by bacterial superinfection.	<input type="checkbox"/> 1
The patient can state precisely the date of the first clinical manifestation of the mast cell mediator syndrome because it is appears to him associated with an infectious disease.	<input type="checkbox"/> 1

Molderings G *et al.* Die systemische Mastzellenkrankung mit gastrointestinal betonter Symptomatik - eine Checkliste als Diagnoseinstrument. *Deutsche medizinische Wochenschrift* 2006 Sep 22; 131(38):2095-100.

Alfter K *et al.* New aspects of liver abnormalities as part of the systemic mast cell activation syndrome. *Liver International* 2010;29(2):181-186.

What we learned in medical school about how to diagnose, that symptom A plus physical exam finding B plus test result C should lead you to suspect diagnosis D, utterly fails here because of the extreme heterogeneity of the presentations. Instead, what I have found most useful is to look at the big picture. In diagnosing MCAS I'm looking for either of two of what I'm calling metapatterns – either a situation of multiple chronic ailments often unsatisfactorily responsive to treatment, or a situation of a definitively diagnosed major illness, say a lymphoma, but that diagnosis is insufficient to explain a number of the patient's other symptoms (for example, a lymphoma patient who is routinely having syncope). I don't know if there's a best way to help the medical profession get better at recognizing these metapatterns. Possibilities include questionnaires for patients, and actually Dr. Molderings in Bonn has developed and validated a questionnaire. However, his group focused mainly on patients with predominantly GI symptoms, so I don't know if his questionnaire is going to be valid for the full spectrum of mast cell activation syndrome patients. Alternatively, we might be able to program our electronic medical record systems to watch for these subtle

multisystem patterns that could then alert the physician to the possible presence of MCAS, but that's likely many years off.

**David Girvin:** You ask about how you enhance the medical community's understanding about this disease. It's been my experience that the emergency doctors, after you explain it as an informed citizen, they'll go to Wikipedia and Google, if those two points were the first edited points that grab attention – the number of physicians that come to me afterwards and said you were right x hours later and I know they looked it up. But it's the WHO that irritates it. And it doesn't make any sense relative to that clause....I'm just saying that your community looks...Googles...and it's an opportunity for something that might be worthwhile as opposed to being the bane of all physicians.

**Dr. Afrin:** That's a decent suggestion. We're getting close to the end here.



[Slide 106: MCAS: Diagnosis.]

The Most Important Slide In This Presentation

## MCAS: Diagnosis

- Best diagnostic aids:
  - The hematologist's best friend: a complete history/ROS
  - Faith in Occam's Razor: which scenario is more likely?
    - Multiple diagnoses/problems all independent of each other

vs.



- One diagnosis that's biologically capable of causing all the findings

The hematologist's best friend – actually, any doctor's best friend – is the best way to diagnose this, namely, a complete history and review of systems. And instead of just giving lip service to Occam's Razor, we need to restore our faith in Occam's Razor, because what is more likely: does the patient have multiple diseases all independent of one another, or does the patient have one "root" disease that is biologically capable of causing all of the observed problems? There are exceptions to Occam, of course. For example, people with inborn genetic diseases such as sickle cell anemia, Ehlers-Danlos, or Charcot-Marie Tooth certainly have those diseases, but such unlucky draws in the genetic lottery of life certainly don't make such patients immune to any other disease, and if MCAS truly is a prevalent disease, then it is much more likely than not that one would be able to relatively easily find such congenitally afflicted patients whose full spectrum of illness includes not only the consequences of their inborn problem but also the consequences of MCAS. Similarly, there are people who acquire acute and chronic infectious illnesses due in no way to an MCAS-induced immune deficiency but instead just classic infectivity (for example, a bite from a malarial mosquito). Again, if MCAS truly is a prevalent disease, then it is much more likely than not that one would be able

to relatively easily find such infectiously afflicted patients whose full spectrum of illness includes not only the consequences of their infection but also the consequences of MCAS (which may be intensified by the infection). My point is that although the clinical heterogeneity of MCAS makes it tempting to ascribe – and even Occam favors ascribing – every symptom and finding in an MCAS patient to MCAS, clinicians who deal with MCAS must always remain alert to the prior presence, or development, of other, true non-MCAS illnesses (whether contracted due to MCAS-induced proclivities or not).

[Slides 107-114: MCAS: Treatment.]

## MCAS: Treatment

- 2011: As for mastocytosis
  - Inhibition of mediator production
  - Inhibition of mediator release (stabilization)
  - Blockade of released mediators
  - Rarely: Cytotoxic therapy
  - Even more rarely: Cellular therapy
  - Treatment of secondary issues

## MCAS: Treatment

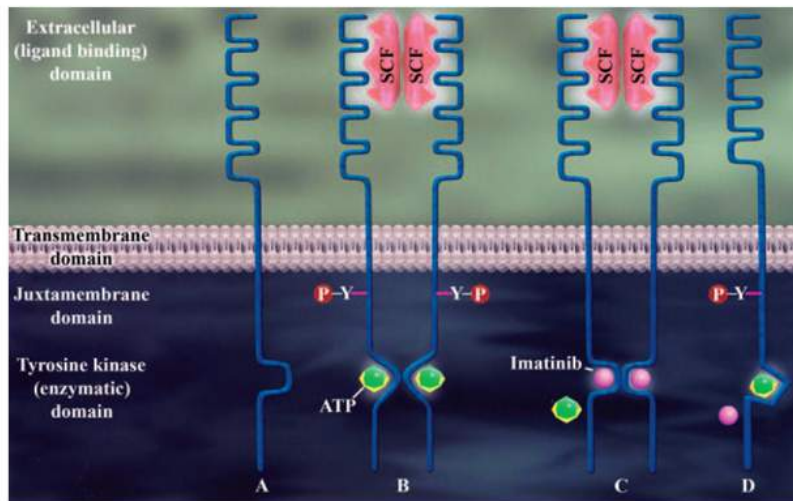
- 2011: As for mastocytosis
  - Inhibition of mediator production
    - Steroids, NSAIDs
    - Possibly also IMiDs
  - Inhibition of mediator release (stabilization)
  - Blockade of released mediators
  - Rarely: Cytotoxic therapy
  - Even more rarely: Cellular therapy
  - Treatment of secondary issues

## MCAS: Treatment

- 2011: As for mastocytosis
  - Inhibition of mediator production
  - Inhibition of mediator release (stabilization)
    - Cromolyn (oral and/or inhaled – non-absorbed)
      - Can trigger flares 1<sup>st</sup> few days; tachyphylaxis can abrogate efficacy
    - Pentosan (especially for interstitial cystitis)
    - Tyrosine kinase inhibitors
      - PEG-interferon
      - Omalizumab (anti-IgE)
      - Azathioprine
      - mTOR inhibitors (e.g., sirolimus)
      - Naltrexone
      - Benzodiazepines and imidazopyridines
        - e.g., lorazepam, clonazepam, flunitrazepam, zolpidem
  - Blockade of released mediators
  - Rarely: Cytotoxic therapy
  - Even more rarely: Cellular therapy
  - Treatment of secondary issues

Imatinib (FDA approved for CML, mastocytosis)  
Dasatinib (FDA approved for CML)  
Nilotinib (FDA approved for CML)  
Midostaurin (investigational)





**FIG 1.** Kit monomer exists in an inactive conformation when unbound to its ligand (A). Cross-linking of Kit by SCF induces a conformational change in the kinase domain, which allows binding of adenosine triphosphate and phosphorylation of tyrosine residues (B). Imatinib binds to the inactive conformation of Kit and inhibits binding of adenosine triphosphate (C). Mutations in enzymatic site or tyrosine kinase domain of the molecule render resistance to imatinib by interfering with its binding to Kit (D).

## MCAS: Treatment

- 2011: As for mastocytosis
  - Inhibition of mediator production
  - Inhibition of mediator release (stabilization)
  - Blockade of released mediators
    - Antihistamines
      - Often impressive benefits even absent rhinosinusitis and dyspepsia
      - Can also stabilize mast cells via their autoexcitatory H<sub>1</sub>/H<sub>2</sub> receptors
    - Leukotriene antagonists
    - Bisphosphonates, Ca<sup>++</sup>/vit. D, denosumab for osteoporosis/osteopenia
    - TNF antagonists (etanercept, adalimumab, infliximab)?
    - IL-1 antagonists (e.g., anakinra), IL-1 $\beta$  antagonists (e.g., canakinumab)?
    - No tryptase inhibitors have made it to phase 2 trials yet
  - Rarely: Cytotoxic therapy
  - Even more rarely: Cellular therapy
  - Treatment of secondary issues

## MCAS: Treatment

- 2011: As for mastocytosis
  - Inhibition of mediator production
  - Inhibition of mediator release (stabilization)
  - Blockade of released mediators
  - Rarely: Cytotoxic therapy
    - Hydroxyurea, alkylators, taxanes, etc.
    - Fludarabine, cladribine, cytarabine, etc.
    - Alemtuzumab, daclizumab
  - Even more rarely: Cellular therapy
  - Treatment of secondary issues

## MCAS: Treatment

- 2011: As for mastocytosis
  - Inhibition of mediator production
  - Inhibition of mediator release (stabilization)
  - Blockade of released mediators
  - Rarely: Cytotoxic therapy
  - Even more rarely: Cellular therapy
    - Allogeneic stem cell transplantation
      - Rarely efficacious
  - Treatment of secondary issues

## MCAS: Treatment

- 2011: As for mastocytosis
  - Inhibition of mediator production
  - Inhibition of mediator release (stabilization)
  - Blockade of released mediators
  - Rarely: Cytotoxic therapy
  - Even more rarely: Cellular therapy
  - Treatment of secondary issues
    - Illnesses secondary to mast cell disease require full treatment until the mast cell disease is controlled, and even then...
    - “...the horse is sometimes already out of the barn”: malignancy and autoimmunity rarely, if ever, spontaneously remit simply with control of the underlying mast cell disease

We don't have time for details, but shown on these slides are the general strategies for treatment of MCAS. You can inhibit mediator production, and there are various approaches to doing that. You can inhibit mediator release or stabilize the mast cell, and there are a variety of treatments for doing that. You can block the mediators after they've already been released (for example, with antihistamines). (By the way, there are both H<sub>1</sub> and H<sub>2</sub> receptors on the mast cell surface. There also are H<sub>3</sub> and H<sub>4</sub> receptors, but there seem to be far fewer of those receptors than of H<sub>1</sub> and H<sub>2</sub>, and besides, we don't have any commercially available medications for blocking H<sub>3</sub> and H<sub>4</sub> receptors.) In any event, my point is that mast cells are autostimulatory.) You can undertake a usually futile effort to try to kill these cells, and you might get some brief improvement with medications like chemotherapy drugs, but by and large you can't kill these cells. And we don't seem to be able to kill them with cellular therapy, so where stem cell transplantation comes into play here is in patients who have gotten a bad leukemia because of this disease, making them candidates for transplant, but the mast cell disease seems to essentially always persist post-transplant. I don't know of a single case where transplant has truly eradicated mast cell disease. And, finally, you can't forget that some of the secondary problems that arise with this disease, like autoimmunity or malignancy, are pertinent issues once they arise and can have serious



Mastocytosis Society Canada Medical Lecture – June 6, 2011

Contact: [info@mastocytosis.ca](mailto:info@mastocytosis.ca) or [afrinl@musc.edu](mailto:afrinl@musc.edu)

Systemic Mast Cell Disease: An Update – L. Afrin, M.D., Medical University of South Carolina

morbidities and must be treated for all intents and purposes as if they are independent problems. Even if you get the underlying mast cell disease under control, still the horse is already out of the barn, as they say, and you have to deal with that cancer.

[Slide 115: MCAS: Prognosis.]

## MCAS: Prognosis

- Early estimate: After the first three years, survival curves parallel the general population
- No rigorous epidemiologic studies

Roberts LJ, Anthony LB, Oates JA. "Disorders of Vasodilator Hormones: Carcinoid Syndrome and Mastocytosis" in Wilson JD, Foster DW, Kronenberg HM, et al., eds., *Williams Textbook of Endocrinology*, 9th ed., 1998, W. B. Saunders Company, Philadelphia, pp. 1718-1732.

We have essentially no credible data regarding prognosis in MCAS. There was one estimate by Dr. Jack Roberts of Vanderbilt back in 1998 that if you survive the first three years from diagnosis, it appears that your survival is going to be equivalent to the general population, but it's going to be a life of chronic misery until the disease gets properly diagnosed and treated. You can imagine the difficulty of trying to do rigorous epidemiological studies in a disease that is capable of presenting like anything.

[Slides 116-120: Case: Smoking is bad for you.]



## Are You Up For One More Case?

- The most outlandish one of all...

## Case: Smoking Is Bad For You

- Soon after relocating from California to Louisiana in 1999, a 35 year old previously very fit man began suffering frequent idiopathic syncope, migraines, fevers, chills, pruritus, sweats, eye irritation, chest pain, GERD, nausea, diarrhea, abdominal pain, rashes, edema, neuropathy, cognitive dysfunction, odd medication reactions (e.g., Benadryl-induced pruritus).
- Relocated to South Carolina in 2001
- Multiple MIs and TIAs/CVAs over the next decade

## Case: Smoking Is Bad For You

- Compound heterozygous MTHFR mutation and lupus anticoagulant found
- Referred in 2011 for further evaluation and management of hypercoagulability
- Additional history: new episodes since 2010 of spontaneous bruise-like welts (wife suspected of spousal abuse) and spontaneous emanation of smoke from all about his body
- Urinary PGD<sub>2</sub> 500 ng/l (normal 100-280)
- Duodenal biopsy: increased mast cells (30/hpf)



## San Francisco Man Catches Fire In Porn Shop

First Posted: 04-14-11 03:40 PM | Updated: 04-14-11 05:33 PM

Follow > [LA News](#), [Engulfed In Flames San Francisco](#), [Man Catches Fire In Porn Shop](#), [SF Porn Fire](#), [San Francisco Porn Shop](#), [San Francisco Man Catches Fire](#), [Porn Fire](#), [Pornography](#), [Los Angeles News](#)

A San Francisco man suffered life-threatening burns after catching fire in an adult video store Wednesday evening.


Lieutenant Kevin McNaughton told [CBS San Francisco](#) news cameras, "at 6:10 this afternoon at the corner of 6th and Mission Street, a man was running out of the adult arcade right behind me that was totally engulfed in flames. Police officers that were immediately across the street called it in."

[SF Appeal](#) reports that after the man collapsed, a private ambulance crew arrived on scene and extinguished the flames, and then "the victim was transported to St. Francis Memorial Hospital's Bothin Bum Center."

It is uncertain how the man caught fire. According to [Fox News LA](#), "police said the man had been watching videos in a private booth when the blaze erupted."

For more, watch the video from CBS below:

Raw Video: San Francisco Porn Store Fire 02:23



SHARE THIS STORY			
Like	1634 likes. Sign Up to see what your friends like.		
430	40	47	172
share	tweet	email	comment

## Case: Smoking Is Bad For You

- Possible mechanism:
  - Adipose tissue (~50B cells) is a mast cell (MC) reservoir
    - Avg. 1000-2000 mitochondria per cell
  - Norepinephrine (NE) is a MC-produced mediator
  - Ordinarily a carefully regulated process, NE switches an adipocyte's mitochondrial UCP-1 to channel energy (released from fatty acid oxidation) into heat release (normally up to 5 nW) instead of ATP prod.
  - Could an unregulated flood of MC NE drive UCP-1 so much that fat escalates to ignition temperature (~90°C)?
  - Once ignited, the fire burns until all fuel (fat) is exhausted

Johannessen EA et al. Micromachined nanocalorimetric sensory for ultra-low-volume cell-based assays. *Anal Chem* 2002, 74:2190-2197.

OK, last case. This is really going to stretch the bounds of the range of illnesses that might be caused by MCAS. It certainly stretched my thinking about MCAS.

Soon after relocating from California to Louisiana in 1999, a 35 year old, previously very fit man began suffering frequent idiopathic syncope, migraines, fevers, chills, buritis, sweats, eye irritation, chest pain, GERD, nausea, diarrhea, rashes, abdominal pain, edema, neuropathy, cognitive dysfunction, and very odd medication reactions. He relocated to my state (South Carolina) a couple of years later and had multiple myocardial infarctions and strokes over the next decade, although none of them ever left any apparent residual damage. He was found on investigation for hypercoagulability to have an inborn mutation which can't really cause all of the heart attack and stroke problems he had had. Another potential source of hypercoagulability, a type of antibody known as lupus anticoagulant, was also found, but it's a bit odd for that disease to primarily manifest with heart attacks and strokes.

So he was referred to me earlier this year for further evaluation of his hypercoagulability. After I got all his history from him, and he saw that for the first time in many years there was a doctor who was taking the time to listen to his full history, he said, "I've got a

couple other things to tell you.” These were not things that were in my review of systems at the time, but they are now. He said, “If I tell you this, you have to promise me first that you will not commit me to a psychiatric hospitalization.” He was dead serious. He said that multiple other physicians had threatened him with psychiatric hospitalization after he revealed what he was about to tell me. So I of course promised him I wouldn’t commit him, and he then told me he had begun having, earlier in the year – 2010 – episodes of spontaneous bruise-like welts erupting all over his body. In one of his visits to the ER for this, he was separated from his wife and he was quizzed about whether his wife was beating him.

And then he had a couple of episodes where he just started feeling very, very hot. Both of these times were when he was undertaking some physical activity. One time was a basketball game, and he had to sit down. He was a little foggy in the head, and a large crowd of people around him all asserted that smoke was emanating from all about his body. This wasn’t vapour, this wasn’t mist; it was smoke, as if from true combustion. In both episodes, the crowd around him took measures to cool him down. One time they put him in a pool, and another time they surrounded him with fans. They got him cooled down after about 30-60 minutes. He cooled down, stopped smoking, and the cognitive dysfunction abated.

Even without the episodes of spontaneous welts at some times and smoking at other times, just from his other symptoms, there was enough to suspect mast cell disease. I did the workup. His PGD<sub>2</sub> urinary was very high and a duodenal biopsy showed increased mast cells, so now the question becomes how one root process can explain everything. We can explain the welts and “bruises,” as that could be due to heparin release into local tissues. He could be having flares of disease with localized eruptions of heparin. But what about the “smoking”?

It turns out there is a phenomenon called spontaneous human combustion. There have been approximately 100 cases reported over the last century. You will not find this in the medical literature because, I’m guessing, physicians simply can’t believe this can happen, thus inclining medical journal editors to reject case reports of such incidents, but it’s certainly in the forensic literature. There are about 100 cases very clearly documented over the last century or so. No cause has ever been found. It was not friction. If you read these cases, there is a unique and consistent pattern of combustion. Most cases are fatal fires. Occasionally you find someone like my patient who only “smoked.”

The combustion pattern is that all the fat and all the bones (note bones contain marrow which has a lot of fat in it) are reduced to ash. All other organs are left largely intact, perhaps just a little bit charred. If it happens indoors, there is a pink grease stain on the ceiling, and I’m guessing that’s just burned fat. And any flammable material that is either in contact with the body or immediately within millimetres of the body, material that should have caught on fire if this were a normal fire, did not catch on fire.

So I started thinking about this. Again, what would Occam's Razor say about this? It's almost certain there's only one thing going on here and that it's mast cell disease. So how can mast cell disease possibly produce spontaneous human combustion?

I started doing some reading and calculating. This is entirely hypothetical. I haven't presented this anywhere before. But here is a possibility, that's all I'm saying, a possibility.

The average trim adult has 50 billion adipose cells. The average obese adult has 70 billion adipose cells. Adipose tissue is a known mast cell reservoir. There are about 1-2,000 mitochondria per adult animal cell, and it is the mitochondria that are the source of heat in your body. Now, we also know that norepinephrine is a known mast cell mediator. It is produced by the mast cell.

In what is normally a very carefully regulated process (as you might imagine), norepinephrine affects a cell's mitochondrial UCP1 protein. This is a switch in the mitochondria that ordinarily channels energy released from fatty acid oxidation of the mitochondria into ATP production. But in the presence of norepinephrine, UCP1 is switched to a different state such that the energy being released by fatty acid oxidation is just released as heat.

So is it possible that an unregulated flood of norepinephrine (or some other mediator which serves to switch UCP1) from a mast cell flare in the adipose tissue could drive UCP1-mediated heat release so much that the fat escalates to ignition temperature (which is less than you might think, a little bit below the boiling point of water). The average cell is capable of producing 5 nanowatts of heat under ordinary circumstances, so if I'm doing the math right, the human body can produce 250 watts of heat per second. Of course, when you escalate temperature of the body to that degree, you very quickly get brain shutdown, the patient dies, and there's no way the mast cells are continuing to release the norepinephrine, but by that point it doesn't matter anymore. The fire has started and it will continue until all the fuel – that is, all the fat – is consumed. This is all hypothetical. I have not a clue how spontaneous combustion actually happens because it's never been observed, and never will be observed, under controlled conditions. However, I've become a big believer in Occam's Razor, and if mast cell disease is causing all the rest of this patient's problems, it seems most likely it's causing his smoking, too. The only question becomes "How?"



[Slide 121: MCAS: What's next?]

## MCAS: What's next?

- **RESEARCH**

- Epidemiology

- Disease associations

- Tie-ins with emerging developed-world epidemics of asthma, allergy, GERD, IBS, obesity, metabolic syndrome, chronic fatigue syndrome, fibromyalgia, etc.; Gulf War illness, too?

- Etiology

- Environmental? Genetic? Epigenetic? Viral?

- Genotype-phenotype correlations

- Targeted therapies

- **EDUCATION** (patients, providers, payers)

Poglio S. et al. Adipose tissue as a dedicated reservoir of functional mast cell progenitors. *Stem Cells* 2010;28:2065-2072.  
Gabbert C et al. Adenovirus 36 and obesity in children and adolescents. *Pediatrics* 2010;126:721-726.

We obviously need to do a whole lot more research. We need to better understand what diseases that presently are idiopathic are actually just different flavours, different presentations of mast cell disease. I'm trying to get a study going with the U.S. Veterans Affairs Dept. The U.S. sent 700,000 military servicemen and servicewomen to the Gulf War in the early 1990s. Three hundred thousand came back with serious, chronic multi-system illness (many of them different from one another) we've taken to calling Gulf War Syndrome or Illness. Twenty years' and a billion dollars' worth of research later, we still don't have a clue why they are sick. However, in my work at the VA in Charleston, I've seen a number of these Gulf War Syndrome patients, and I feel their clinical profile just reeks of mast cell disease. I've actually been able to do partial workups in two of them so far, and they're both positive for mast cell disease. So I'd like to rigorously study this because if we get answers to what's making 300,000 people sick...well, let me ask you this, as this segues greatly into the scale of MCAS – how many patients have CML? What's the incidence of CML? Oh, sorry, I'm guessing you wouldn't know the U.S. figures, but it's about 8,000 people per year.



**Dr. Trinkaus:** In Canada, it's 800 cases per year.

**Dr. Afrin:** The total U.S. population of CML patients is about 50,000. So if Gulf War Syndrome turns out to be due to MCAS, this finding would instantly dramatically expand the scale of chronic myeloproliferative disease in the U.S. even if one doesn't believe that MCAS might cause all the other illnesses I previously mentioned I suspect it causes. I don't have proof of this MCAS/Gulf-War-Syndrome connection yet, and the studies will be challenging, but from what I've been seeing the past three years, I believe I have good reason to suspect that mast cell activation syndrome is a whole lot more common than any of the diseases for which the tyrosine kinase inhibitors are being targeted. Time will tell.

We also need to better understand the etiology and epidemiology of MCAS. There clearly are many families out there with multiple members of the family with mast cell activation syndrome, but often different members of the same family have very different presentations. What we think is going on is that although the KIT mutations and the other mast cell regulatory protein mutations themselves are not being inherited, there is some sort of a susceptibility factor (possibly an epigenetic factor) that's being inherited, and that factor is interacting with unknown environmental factors – more commonly early in life rather than later – and the interaction of the trigger with the susceptibility factor is then what leads to the mutations that we know are there in MCAS. But different triggers interacting with the susceptibility factor may lead to the different mutations, explaining how different members of the same family get different flavours of mast cell activation syndrome.

We need to get to the point where we are routinely sequencing at least KIT, and preferably the entire genome, and that's not as farfetched as you might think. We're probably about 5-10 years away from this. Once we know the mutations, then we can start correlating the mutations with the pattern of abnormal mediators that are present in the individual patient, then correlate that with symptoms, correlate that with response to treatment, and we'll finally get to a point – we're easily talking 15-20 years in development here – where the disease gets suspected, it gets diagnosed, you get a sequence, and based on the sequence you can predict which treatments are most likely to help that patient.

We clearly also need better education about mast cell disease for medical professionals of all stripes.

I apologize for running late. This is basically everything I've learned about this since I first began to recognize it in 2008. Thank you.

**Remainder of audio is discussion amongst doctors about questions, tests to run, symptom presentations, etc.**